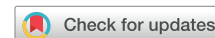

# A Lexicon for First-Trimester US: Society of Radiologists in Ultrasound Consensus Conference Recommendations



Shuchi K. Rodgers, MD; Mindy M. Horrow, MD; Peter M. Doubilet, MD, PhD;  
Mary C. Frates, MD; Anne Kennedy, MB, BCh; Rochelle Andreotti, MD;  
Kristyn Brandi, MD, MPH; Laura Detti, MD; Sarah K. Horvath, MD, MSHP; Aya Kamaya, MD;  
Atsuko Koyama, MD, MPH; Penelope Chun Lema, MD; Katherine E. Maturen, MD, MS;  
Tara Morgan, MD; Sarah G. Obican, MD; Kristen Olinger, MD; Roya Sohaey, MD;  
Suneeta Senapati, MD; Lori M. Strachowski, MD

The Society of Radiologists in Ultrasound convened a multisociety panel to develop a first-trimester US lexicon based on scientific evidence, societal guidelines, and expert consensus that would be appropriate for imagers, clinicians, and patients. Through a modified Delphi process with consensus of at least 80%, agreement was reached for preferred terms, synonyms, and terms to avoid. An *intrauterine pregnancy* (IUP) is defined as a pregnancy implanted in a normal location within the uterus. In contrast, an *ectopic pregnancy* (EP) is any pregnancy implanted in an abnormal location, whether extrauterine or intrauterine, thus categorizing cesarean scar implantations as EPs. The term *pregnancy of unknown location* is used in the setting of a pregnant patient without evidence of a *definite* or *probable* IUP or EP at transvaginal US. Since cardiac development is a gradual process and cardiac chambers are not fully formed in the first trimester, the term *cardiac activity* is recommended in lieu of 'heart motion' or 'heartbeat.' The terms 'living' and 'viable' should also be avoided in the first trimester. 'Pregnancy failure' is replaced by *early pregnancy loss* (EPL). When paired with various modifiers, *EPL* is used to describe a pregnancy in the first trimester that may or will not progress, is in the process of expulsion, or has either incompletely or completely passed.

**Abbreviations:** ACOG: American College of Obstetricians and Gynecologists, EP: ectopic pregnancy, EPL: early pregnancy loss, GA: gestational age, GS: gestational sac, hCG: human chorionic gonadotropin, IUP: intrauterine pregnancy, PUL: pregnancy of unknown location, RPOC: retained (or residual) products of conception, SRU: Society of Radiologists in Ultrasound

From the Department of Radiology, Thomas Jefferson University, Philadelphia, Pa (S.K.R.); Department of Radiology, Einstein Healthcare Network/Jefferson Health, Philadelphia, Pa (M.M.H.); Department of Radiology, Brigham and Women's Hospital/Harvard Medical School, Boston, Mass (P.M.D., M.C.F.); Department of Radiology and Imaging Sciences, University of Utah, Salt Lake City, Utah (A. Kennedy); Department of Radiology and Radiological Sciences and Department of Obstetrics and Gynecology, Vanderbilt University, Nashville, Tenn (R.A.); American College of Obstetricians and Gynecologists, Newark, NJ (K.B.); Department of Obstetrics and Gynecology, Baylor College of Medicine, Houston, Tex (L.D.); Department of Obstetrics and Gynecology, Pennsylvania State University, University Park, Pa (S.K.H.); Department of Radiology, Stanford University, Stanford, Calif (A. Kamaya); Division of Child Health, University of Arizona College of Medicine Phoenix, Phoenix, Ariz (A. Koyama); Department of Emergency Medicine, Columbia University, New York, NY (P.C.L.); Department of Radiology and Department of Obstetrics and Gynecology, University of Michigan, Ann Arbor, Mich (K.E.M.); Department of Radiology, Mayo Clinic Arizona, Phoenix, Ariz (T.M.); Department of Obstetrics and Gynecology, University of South Florida, Tampa, Fla (S.G.O.); Department of Radiology, University of North Carolina, Chapel Hill, NC (K.O.); Department of Diagnostic Radiology, Oregon Health & Sciences University, Portland, Ore (R.S.); Department of Obstetrics and Gynecology, University of Pennsylvania, Philadelphia, Pa (S.S.); and Department of Radiology and Biomedical Imaging and Department of Obstetrics, Gynecology and Reproductive Sciences, University of California San Francisco, 1001 Potrero Ave, 1X57, San Francisco, CA 94110 (L.M.S.).

Received Jan. 23, 2024; revised March 11, 2024; accepted June 14, 2024.

Conflicts of interest are listed at the end of this article.

See also the editorial by Scoutt and Norton in this issue.

Radiology 2024:e240122 • <https://doi.org/10.1148/radiol.240122> • Content codes:

Deputy Editor: Vicky Goh

Supplemental material is available for this article.

This article is a simultaneous joint publication in *Radiology* and *American Journal of Obstetrics & Gynecology*. All rights reserved. The articles are identical except for minor stylistic and spelling differences in keeping with each journal's style. Either version may be used in citing this article.

Address correspondence to L.M.S. [lori.strachowski@ucsf.edu](mailto:lori.strachowski@ucsf.edu)

0002-9378/\$36.00 • © 2024 Elsevier Inc. and RSNA. • <https://doi.org/10.1016/j.ajog.2024.07.038>

Click Video under article title in Contents at [ajog.org](https://ajog.org)

Early pregnancy US is a common diagnostic imaging study. The indications for a first-trimester US examination include confirmation of pregnancy, dating, visualization of cardiac activity, vaginal bleeding, determination of pregnancy location and number, pelvic pain, clinical factors, and follow-up of prior imaging findings<sup>1–3</sup>. While there is multisociety agreement for first-trimester imaging guidelines<sup>1</sup> and consensus-based criteria for reliable sonographic findings to predict which pregnancies will not progress<sup>3</sup>, there is lack of consensus on terms commonly used in the medical record (including the US report) and in communicating with patients. Many terms in current use are not explicitly defined, are used inconsistently, have implications that have evolved over time, or may be interpreted differently by radiologists, clinicians, and patients.

While individual organizations have endorsed or recommended specific first-trimester terminology<sup>4–7</sup>, a multisociety and multispecialty approach can better achieve widely adopted and consistent language to avoid misunderstandings and potential harm to patients and their pregnancies. Patient preference for and against certain terminology should also be considered, particularly as patients increasingly have rapid access to their medical records. In addition, after the 2022 Dobbs v Jackson Women's Health Organization Supreme Court decision gave U.S. states the right to regulate abortion access<sup>8</sup>, US findings and conclusions as well as specific language in the medical record could be used by legal and political communities to negatively affect the physician-patient relationship and criminalize patients and practitioners<sup>9</sup>.

Thus, to minimize preventable adverse outcomes and to protect patients and clinicians, the Society of Radiologists in Ultrasound (SRU) convened a multisociety panel of experts to develop a lexicon for first-trimester US reports. The goal was to identify terms that (a) are clear, specific, scientifically based, and medically appropriate; (b) are acceptable to imagers, clinicians, and patients; and (c) minimize bias and harm.

## SUMMARY

The Society of Radiologists in Ultrasound First-Trimester US Lexicon recommends well-defined, scientific, and specific terminology to communicate clearly across disciplines, minimize bias and harm, and respect patient preferences.

The scope of this lexicon is limited to terms generally unique to and frequently encountered during the first trimester. Terms specifically related to multiple gestations, morphologic anomalies, and gestational trophoblastic disease were omitted. Additional excluded terms were general descriptors not specific to pregnancy, such as “corpus luteum,” “hematoma,” and “hemoperitoneum.” When addressing the indication for examination, members preferred using clinical signs and symptoms rather than suspected diagnoses, such as “missed abortion.”

This first-trimester US lexicon is organized into four major categories: general first-trimester terms, early development, pregnancy location, and early pregnancy loss. For clarity, approved lexicon terms are italicized and bolded, alternate or optional terms are italicized, and single quotation marks identify terms to avoid.

## Materials and Methods

A Memorandum of Understanding for the SRU Consensus Conference to develop a lexicon for first-trimester US was entered into agreement among the SRU and the following societies: the Society of Abdominal Radiology, the American College of Radiology, the American College of Obstetricians and Gynecologists (ACOG), the American Institute of Ultrasound in Medicine, the Society for Maternal-Fetal Medicine, the American Society for Reproductive Medicine, the Society of Family Planning, and the American College of Emergency Physicians. The intent of the memorandum was to prevent duplicative efforts and promote uniform adoption. Panel members were nominated by each society and invited by the panel chair (S.K.R.). To achieve inclusive representation and a broad range of perspectives, panel members were

recruited from across the United States, including Arizona, California, Florida, Massachusetts, Michigan, New Jersey, New York, Oregon, Pennsylvania, Tennessee, Texas, and Utah.

The panel met between January and July 2023 under the direction of the steering committee (S.K.R., M.M.H., and L.M.S.). Categories of terms were assigned to subgroups of panel members who performed an extensive literature search using PubMed and Ovid to include existing guidelines, standards, societal lexicons, and clinician and patient preferences surveys. Subgroup presentations to the full panel included recommendations for a preferred term and synonyms and terms to avoid, with an accompanying definition, application of the term, or a description of the sonographic observation to which the term refers. For terms that did not reach unanimous agreement, a modified Delphi process<sup>10–12</sup> was used to attain at least 80% agreement with use of survey polls written by the steering committee. All participating societies fully endorse this first-trimester US lexicon.

## First-Trimester Lexicon Terms

### General Terms

The panel decided it was prudent to include nonimaging terms that appear in the definition or application of other lexicon terms (Fig 1). These include definitions of pregnancy and the first trimester.

### ***Pregnancy and human chorionic gonadotropin***

During pregnancy, trophoblastic cells produce the hormone ***human chorionic gonadotropin*** (hCG). A patient is considered pregnant when the serum hCG value is greater than 5 mIU/mL. Given the multitude of hCG assays available, specific values and

KEY RESULTS

- *Early pregnancy loss* replaces ‘pregnancy failure’ and is used with the following modifiers: *concerning for*, *diagnostic of*, *in progress*, *incomplete*, and *completed*.
- *Cardiac activity* replaces ‘heart motion’ in the first trimester, and ‘live,’ ‘living,’ and ‘viable’ should also be avoided.
- *Ectopic pregnancy* is defined as an abnormal pregnancy implantation and includes both extrauterine and intrauterine sites, such as the cervix or cesarean scar.

terminology may vary, and centers are encouraged to refer to local laboratory guidelines.<sup>13,14</sup> For example, the modifier *beta* is not used by some laboratories. Values of 5 mIU/mL or less may occur in healthy nonpregnant patients.<sup>12</sup> Rarely, elevated hCG levels may be unrelated to

pregnancy, such as with pituitary dysfunction or neoplasia.<sup>13,15</sup>

**Gestational age and the first trimester**

The duration of pregnancy is called **gestational age** (GA) and is reported as number of weeks and number of days. GA

is calculated by the best obstetric estimate, typically using the first day of the last menstrual period and/or an early-dating US examination.<sup>16</sup> Alternate terms for GA are *menstrual age*, *gestational duration*, *clinical age*, or *clinical dates*. In the setting of assisted reproduction, a pregnancy is dated based on clinical factors such as the time of intrauterine insemination or embryo transfer and is beyond the scope of these guidelines. The **first trimester** of pregnancy is defined as a GA of 13 weeks 6 days or less.<sup>1,16,17</sup> The term *normal* should only be used to describe the first-trimester US examination characteristics, such as *normal first-trimester US examination* or *normal location*. ‘Normal



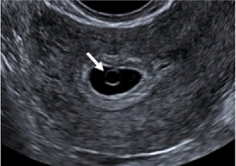
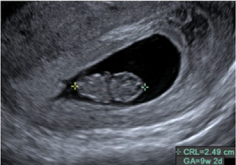

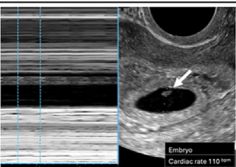
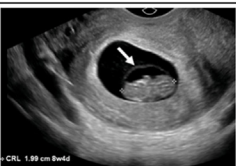
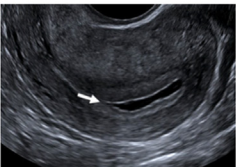
FIGURE 1  
General terms

SRU FIRST TRIMESTER ULTRASOUND LEXICON: GENERAL TERMS			
Term(s) Alternate Term(s)	Application/ Definition	Term(s) to Avoid	Comments
<b>hCG</b>	Human chorionic gonadotropin		<ul style="list-style-type: none"><li>Produced by trophoblastic cells</li><li><i>Beta</i> modifier may no longer be used by some laboratories</li></ul>
<b>Pregnant</b>	Serum hCG >5 mIU/mL		<ul style="list-style-type: none"><li>Refer to local laboratories for discriminatory hCG value</li><li>hCG ≤5 mIU/mL may occur in healthy non-pregnant patients</li><li>Rarely, elevated hCG may be unrelated to pregnancy such as with pituitary dysfunction or neoplasia</li></ul>
<b>Gestational age</b> <i>Menstrual age</i> <i>Gestational duration</i> <i>Clinical age or dates</i>	Duration of pregnancy		<ul style="list-style-type: none"><li>Reported as # weeks # days</li><li>Based on 1<sup>st</sup> day of LMP and/or early dating US</li><li>In setting of assisted reproductive technologies, pregnancy is dated by clinical factors such as time of intrauterine insemination or embryo transfer, etc.</li></ul>
<b>First (1<sup>st</sup>) trimester</b>	GA ≤13 weeks 6 days		
<b>First (1<sup>st</sup>) trimester US</b> <i>Early pregnancy US</i> <i>Obstetrical (OB) US</i>	US exam in the 1 <sup>st</sup> trimester of pregnancy	‘Viability’ scan	<ul style="list-style-type: none"><li><i>Normal</i> modifier may be used to describe the US examination or pregnancy location; caution against: ‘normal 1<sup>st</sup> trimester pregnancy’ as anomalies may be missed early in pregnancy</li><li>Clinical indications include confirmation of pregnancy, dating, presence of cardiac activity, determining pregnancy location and number, vaginal bleeding, pain, etc.</li></ul>

SRU = Society of Radiologists in Ultrasound; hCG = human chorionic gonadotropin; mIU/mL = milli-international units per milliliter; # = number; LMP = last menstrual period; GA = gestational age; US = ultrasound

Lexicon terms (bolded and/or italicized) applicable to pregnancy but not specific to imaging are listed in this table.

**FIGURE 2**  
**Early development**

 <b>SRU FIRST TRIMESTER ULTRASOUND LEXICON: EARLY DEVELOPMENT</b>					
Term(s) Alternate term(s)	Image Example(s)	Image Key	Definitions/ Applications	Term(s) to Avoid	Comments
<b>Gestational sac</b> <i>Pregnancy</i>		Arrow = GS	Round or oval fluid collection surrounded by hyperechoic rim of trophoblastic tissue, ± YS, ± embryo		<ul style="list-style-type: none"> <li>Visualized on TVUS at ~ 5 weeks GA</li> <li>May be intrauterine or ectopic</li> <li>No YS or embryo = <b>probable GS/pregnancy</b></li> <li>With YS or embryo = <b>definite GS/pregnancy</b></li> <li><b>Intradecidual sign</b> and <b>double decidual sac sign</b> helpful when seen but not required</li> <li><b>Mean sac diameter (MSD)</b> = (L+W+H)/3; used for calculating GA before embryo is seen</li> </ul>
<b>Yolk sac</b>		Arrow = YS	Thin rimmed circular structure eccentrically located in GS		<ul style="list-style-type: none"> <li>Visualized on TVUS at ~ 5 ½ weeks GA</li> <li>Confirms <b>definite GS/pregnancy</b></li> <li>Typically, ≤6 mm</li> </ul>
<b>Embryo/Fetus</b>		Calipers = embryo (CRL = 25 mm)	Embryo = GA ≤10 weeks 6 days	Embryonic 'pole'	<ul style="list-style-type: none"> <li>Embryo with cardiac activity is visualized on TVUS at ~ 6 weeks GA</li> <li><b>Crown-rump length (CRL)</b> = greatest dimension of embryo/fetus; used for dating when embryo/fetus present</li> <li>Per AIUM Practice Parameters:               <ul style="list-style-type: none"> <li>Embryonic/fetal number required to determine singleton vs. twins vs. higher order multiples</li> </ul> </li> <li>Report chorionicity (# of sacs) and amnionicity (when possible) for all multi-gestation pregnancies</li> </ul>
		Calipers = fetus (CRL = 74 mm)	Fetus = GA ≥11 weeks 0 days	Fetal 'pole'	
<b>Cardiac activity</b> <i>Cardiac motion</i>		Arrow = embryo Left half of screen = M-mode	Rhythmic pulsations in embryo/fetus	'Heart' 'Live', 'living' 'Viable'	<ul style="list-style-type: none"> <li>Avoid all phrases containing 'heart' (e.g., 'heart motion', 'heartbeat', 'heart tones', etc.) and 'live', 'living' and 'viable' in 1<sup>st</sup> trimester</li> <li>Document with M-mode or cine clip</li> <li><b>Beats per minute (bpm)</b> = rate of cardiac activity</li> </ul>
<b>Amnion</b>		Arrow = amnion	Thin membrane surrounding embryo/fetus within GS		<ul style="list-style-type: none"> <li>Visualized on TVUS at ~ 7 weeks GA</li> <li><b>Amniotic cavity</b> = fluid-filled space contained by amnion</li> <li>YS always outside amniotic cavity</li> </ul>
<b>Intracavitary Fluid</b> <i>Endometrial cavity fluid</i>		Arrow = pointed margin	Fluid in endometrial cavity with pointed/non-curved margins, ± internal echoes	'Pseudo-gestational sac' 'Pseudosac'	<ul style="list-style-type: none"> <li>Avoid 'pseudogestational sac' and 'pseudosac' as may be misinterpreted as indicating presence of ectopic pregnancy (even without other findings) leading to clinical errors</li> </ul>

SRU = Society of Radiologists in Ultrasound; GS = gestational sac; "±" = with or without; YS = yolk sac; TVUS = transvaginal US; "~" = approximately; L = length; W = width; H = height; GA = gestational age; AIUM = American Institute of Ultrasound in Medicine; 1<sup>st</sup> = first

Lexicon terms (bolded and/or italicized) in this table relate to structures visualized at US in early pregnancy development. Terms to avoid are in single quotation marks. Terms specific to multigestation pregnancies, such as *chorionicity* and *amnionicity*, are beyond the scope of this lexicon.

first-trimester pregnancy' should be avoided since abnormalities may be undetectable at this early GA.

#### Early Development

The terms related to early development considered by the panel were based on

the American Institute of Ultrasound in Medicine practice parameters, including the number of gestational sacs (GS), yolk



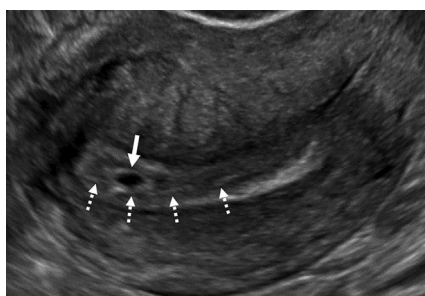
sacs, and embryos and presence of cardiac activity<sup>1</sup> (Fig 2). In the setting of a multigestation pregnancy, descriptors for chorionicity and amnionity are required but are beyond the scope of this lexicon; the reader is referred to the published literature for these terms.<sup>18</sup> It is important to note that visualization of an embryo is required to determine whether there is a singleton or twin pregnancy. For instance, an early monochorionic twin pregnancy will appear as a single GS. Therefore, before visualization of an embryo, this appearance should be reported as a *single GS* rather than as a ‘single pregnancy.’ To be clear, all measurements and timing of visualization of structures in early pregnancy are applicable to transvaginal US imaging.

### Gestational sac, yolk sac, and intracavitary fluid

A GS, intrauterine or ectopic in location, is the earliest sonographic finding of pregnancy and is typically visualized at 5 weeks GA<sup>19,20</sup> as a round or oval fluid collection surrounded by a hyperechoic rim of trophoblastic tissue.<sup>21</sup> The *yolk sac*, a thin-rimmed circular structure eccentrically located within a GS, is visualized at approximately 5 1/2 weeks GA<sup>22</sup> and typically measures less than 6 mm.<sup>23,24</sup> The presence of a yolk sac within an intrauterine fluid collection is incontrovertible evidence of a pregnancy, and the sonogram should be interpreted as demonstrating a *definite GS* or *definite pregnancy*. Without visualization of a yolk sac or embryo, the fluid collection is still highly likely to represent a pregnancy.<sup>25,26</sup> To reflect this slightly less definitive situation, an empty sac should be reported as a *probable GS* or *probable pregnancy*.<sup>27,28</sup>

The *intradecidual sign*<sup>29–31</sup> (Fig 3) and *double decidual sac sign*<sup>32</sup> (Fig 4) can be used to increase confidence in interpreting an empty GS as an *intrauterine pregnancy* (IUP). These signs are highly specific but not sensitive, with reported poor interobserver agreement.<sup>33</sup> Thus, the presence of these signs is not required to diagnose an IUP but may be helpful when present. The *mean*

**FIGURE 3**  
**Intradecidual sign**



Transvaginal sagittal grayscale US image in a 34-year-old pregnant patient shows a 4-mm empty gestational sac (GS) (solid arrow) in the anterior endometrium. The location of the GS to one side of the central hyperechoic line (dotted arrows) representing the opposed innermost layers of decidualized endometrium confirms it is within endometrium and not the endometrial cavity, hence the name *intradecidual sign*. This sign is helpful when seen to diagnose a *probable* intrauterine pregnancy (IUP) before visualization of the yolk sac. Three days later, the yolk sac was visualized (not shown), allowing for the diagnosis of a *definite* IUP.

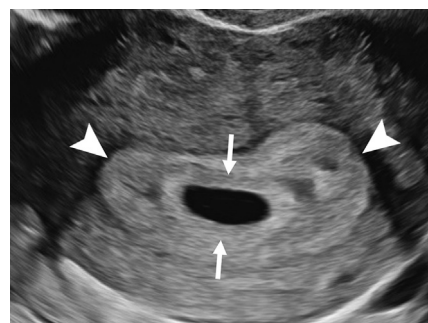
*sac diameter* can be used to calculate the GA before visualization of an embryo.

Fluid in the endometrial cavity in a pregnant patient may have an appearance that mimics a GS and historically has been called a ‘pseudosac’ or ‘pseudogestational sac.’<sup>34,35</sup> These terms were introduced when obstetric US originated but should be avoided, as they may lead to clinical errors. For example, a pseudosac interpreted as evidence of an ectopic pregnancy (EP) without any other findings of an EP may lead to treatment potentially harming an early IUP. Conversely, a pseudosac may be mistaken for an intrauterine GS, dismissing the possibility of an EP. Fluid in the endometrial cavity with pointed or noncurved margins and variable internal echoes should therefore be described as *intracavitary fluid* or *fluid in the endometrial cavity*.

### Embryo and fetus

An embryo with cardiac activity is typically visualized at 6 weeks GA.<sup>19,20</sup> Many

**FIGURE 4**  
**Double decidual sac sign**


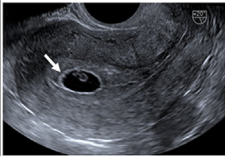
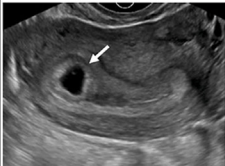
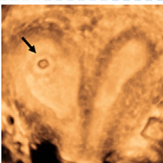


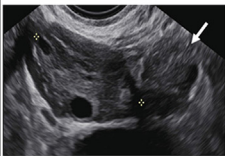




Transvaginal transverse grayscale US image in a 27-year-old pregnant patient at 5 weeks 3 days shows two concentric echogenic rings around an oval fluid collection representing the *double decidual sac sign*. The inner echogenic ring (arrows) corresponds to trophoblastic chorion and decidua capsularis. The outer echogenic ring (arrowheads) represents decidua vera and endometrial lining. The double decidual sac sign is more specific for an intrauterine pregnancy than the intradecidual sign when the gestational sac is empty.

societies use the 10th week of pregnancy as the transition point to apply the term embryo versus fetus. However, there are differences in the literature regarding the precise number of weeks and days to make the distinction.<sup>36</sup> This is largely due to the occasionally interchangeable use of the term GA, based on last menstrual period or early-dating US, and the terms ‘conceptual age’ and ‘fetal age,’ based on the timing of ovulation and conception. As the duration of pregnancy is conventionally reported as GA and refers to completed weeks from the first day of the last menstrual period, the consensus is that an *embryo* is 10 weeks 6 days GA or less.<sup>1,17,37</sup> Beginning at 11 weeks 0 days GA, the conceptus should be referred to as a *fetus*.<sup>17</sup>

The word ‘pole,’ as in ‘embryonic pole’ or ‘fetal pole,’ is obsolete and should be avoided. The term for measurement of an embryo or fetus based on its greatest dimension is *crown-rump length*. As soon as an embryo is measurable, the crown-rump length should be used for

**FIGURE 5**  
**Pregnancy location**

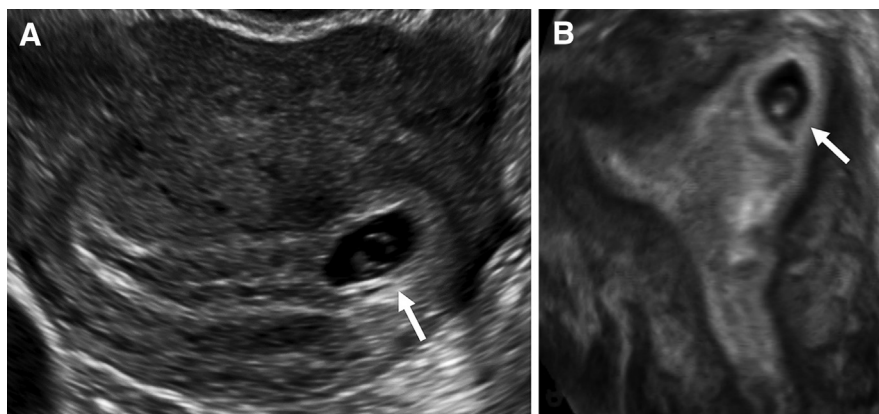
 <b>SRU FIRST TRIMESTER ULTRASOUND LEXICON: PREGNANCY LOCATION</b>					
Term(s) Alternate Term(s)	Image Example(s)	Image Key	Definitions/ Applications	Term(s) to Avoid	Comments
<b>NORMAL</b>					
<b>Intrauterine pregnancy (IUP)</b>  <i>Normally located pregnancy/IUP</i>		Arrow = IUP	Pregnancy implanted in a normal location		<ul style="list-style-type: none"> <li>In early pregnancy, GS normally located in upper 2/3 of uterus</li> </ul>
<b>Variants:</b>  - Eccentrically located GS completely surrounded by endometrium		Arrow = IUP (transverse plane)		'Angular pregnancy' 'Cornual pregnancy' 'Eccentric pregnancy'	<ul style="list-style-type: none"> <li>Conclude as IUP</li> <li>Optional to include description/term in report findings</li> <li>Short-interval follow-up or 3D TVUS may help differentiate from interstitial EP in uncertain cases</li> </ul>
- Describe location of GS in uterus with Müllerian duct anomaly		Arrow = IUP in right horn of septate uterus (3D coronal reconstructed plane)		'Unicornuate pregnancy' 'Bicornuate pregnancy'	<ul style="list-style-type: none"> <li>Reporting examples:               <ul style="list-style-type: none"> <li>GS within a unicornuate uterus</li> <li>GS within right horn of a septate uterus</li> </ul> </li> </ul>
<b>ABNORMAL</b>					
<b>Ectopic pregnancy</b>	 	Arrow = GS in left interstitial segment of tube (transverse plane)  Arrow = CS scar	Pregnancy implanted in an abnormal location	'Cornual EP' 'Cesarean scar pregnancy' 'Cervical pregnancy' 'Live/living EP' 'Viable EP'	<ul style="list-style-type: none"> <li>Poses risk of maternal morbidity/mortality if untreated</li> <li>General term; report laterality (if applicable) and location as follows:               <ul style="list-style-type: none"> <li><b>Tubal EP</b> (includes <i>ampullary</i>, <i>isthmic</i>, &amp; <i>fimbrial</i>)</li> <li><b>Interstitial EP</b> (intra-myometrial segment of tube)</li> <li><b>Cesarean scar EP</b>, <b>cervical EP</b>, <b>ovarian EP</b>, <b>abdominal EP</b>, <b>intramural EP</b></li> </ul> </li> <li>Report YS, embryo/fetus and cardiac activity when seen to assist with treatment planning               <ul style="list-style-type: none"> <li>No YS or embryo/fetus = <b>probable EP</b></li> <li>With YS or embryo/fetus = <b>definite EP</b></li> <li>When in LUS/endocervix, must differentiate from EPL in progress; short-interval follow-up may help in uncertain cases</li> </ul> </li> <li>With co-existing IUP = <b>heterotopic pregnancy</b></li> </ul>
<b>- Extraovarian Mass</b>  <i>Adnexal mass</i>		Solid arrow = extraovarian mass Calipers = ovary	Adnexal mass, separate from ovary, of variable echogenicity and vascularity		<ul style="list-style-type: none"> <li>When no IUP, high likelihood of tubal EP</li> <li><b>Adnexal mass</b> preferred when ovary not seen</li> <li><b>Sliding sign</b> helpful to confirm separate from ovary or uterus</li> </ul>
<b>- Tubal ring</b>  <i>Adnexal ring</i> <i>Adnexal GS</i>		Solid arrow = tubal ring Dotted arrow = ovary	GS in adnexa separate from ovary, ± peripheral vascularity	'Bagel' sign 'Donut' sign	<ul style="list-style-type: none"> <li>When no IUP, high likelihood of tubal EP (even without YS or embryo)</li> <li>Important to differentiate from exophytic corpus luteum               <ul style="list-style-type: none"> <li>Echogenicity, ovarian <b>claw sign</b> and <b>sliding sign</b> on TVUS may be helpful</li> </ul> </li> <li>Color Doppler not useful as both may have a ring of peripheral vascularity</li> </ul>
<b>UNKNOWN</b>					
<b>Pregnancy of unknown location (PUL)</b>		Arrows = ovaries (transverse plane)	No findings of probable or definite IUP or EP on TVUS		<ul style="list-style-type: none"> <li>Differential diagnosis = non-visualized early IUP, non-visualized EP and completed EPL; correlate with trending serum hCG values and follow-up US               <ul style="list-style-type: none"> <li>Most IUPs seen with serum hCG ≥3000 mIU/ml</li> </ul> </li> <li>Should <b>NOT</b> be used when TVUS shows:               <ul style="list-style-type: none"> <li><b>Probable GS/IUP</b> = any round/oval intrauterine fluid collection with a hyperechoic rim (even without YS or embryo)</li> <li><b>Probable EP</b> = no findings of IUP and extraovarian mass or tubal ring (even without YS or embryo)</li> </ul> </li> </ul>

SRU = Society of Radiologists in Ultrasound; GS = gestational sac; 3D = three dimensional; TVUS = transvaginal US; EP = ectopic pregnancy; CS = cesarean section; YS = yolk sac; LUS = lower uterine segment; EPL = early pregnancy loss; "±" = with or without; hCG = human chorionic gonadotropin

The location of a pregnancy is divided into normal, abnormal, and unknown. Lexicon terms are bolded and/or italicized, and terms to avoid are in single quotation marks. The essential word in the definition of intrauterine pregnancy and ectopic pregnancy (EP) is *implanted*, which helps differentiate pregnancies that are temporarily located in the lower uterine segment. This definition also further clarifies abnormal intrauterine implantation sites as EPs.

**FIGURE 6**

**Normal intrauterine pregnancy (IUP) variant: eccentrically located gestational sac (GS) completely surrounded by endometrium**



(A) Transvaginal transverse grayscale and (B) coronal reformatted three-dimensional US image in a 36-year-old pregnant patient shows an off-midline (leftward) GS (arrow) at 5 weeks 4 days with yolk sac and embryo. The GS is completely surrounded by endometrium and may be reported as an IUP without further description. If desired, the user may describe as an *eccentrically located GS completely surrounded by endometrium* but should conclude as an IUP to obviate concern for an interstitial ectopic pregnancy. The terms ‘angular’ or ‘cornual pregnancy’ should be avoided. Coronal reformatted three-dimensional US may help confirm a GS is located within endometrium, as demonstrated in this case.

dating since it is more accurate than the mean sac diameter.

### Cardiac activity

Embryonic or fetal rhythmic pulsations observed in the first trimester should be reported as **cardiac activity**, or alternatively as *cardiac motion*. Historically, the terms ‘heart motion,’ ‘heart activity,’ and ‘heartbeat’ have been used. However, the term ‘heart’ implies a fully formed organ, and cardiac development is gradual and incomplete during the GAs discussed in this document.<sup>17,38</sup> *Cardiac* is a scientifically accurate adjective and is endorsed by ACOG.<sup>6</sup> The rate of cardiac activity, as documented on M-mode, should be reported as **beats per minute**.

The terms ‘live,’ ‘living,’ and ‘viable’ have been used frequently to refer to any pregnancy with cardiac activity. We recommend against the use of all these terms in the first trimester. ‘Live’ and ‘living’ are best avoided because these terms may be appropriated by people outside of the field of medicine to support political rhetoric and proscriptive

legislation. In addition, these terms may raise unrealistic expectations for patients facing potential pregnancy loss or EPs. Fetal viability has been defined as the ability of a fetus to survive in the extra-uterine environment<sup>39</sup> and thus is not applicable in the first trimester.<sup>3</sup> Avoiding the terms ‘nonviable’ and ‘pregnancy of uncertain viability’ is therefore recommended. Likewise, a US examination in the first trimester should be called **first-trimester US** or **early pregnancy US** and not a ‘viability’ scan.

### Amnion and amniotic cavity

The thin membrane surrounding an embryo or fetus within a GS is called the **amnion** and is typically visualized at 7 weeks GA.<sup>40</sup> The fluid-filled space contained by the amnion is the **amniotic cavity**.

### Pregnancy Location

Terms to describe the location of a pregnancy are divided into three sub-categories: normal, abnormal, and unknown (Fig 5).

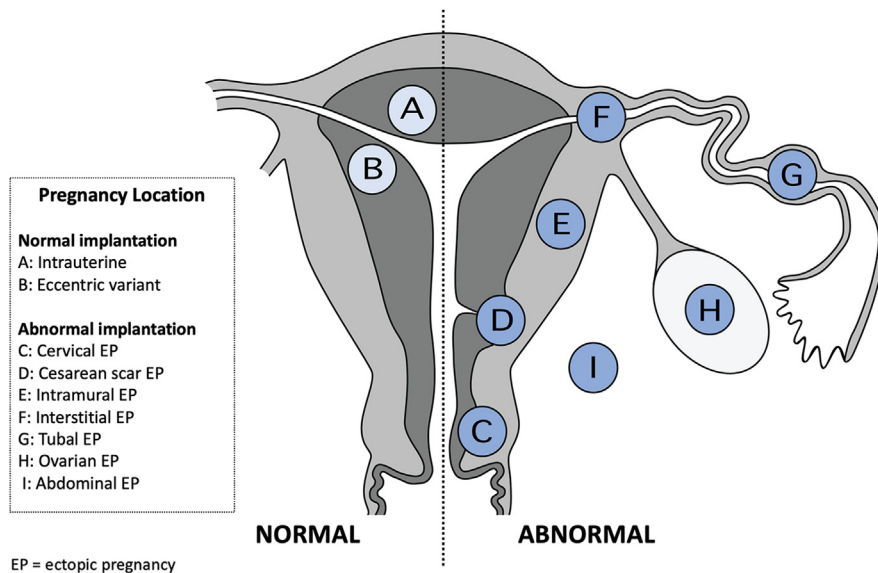
### Normal: IUP and variants

In a normally located pregnancy, the GS is located within decidualized endometrium in the upper two-thirds of the uterine cavity. The most common term to describe a normal pregnancy location is **IUP**, and the consensus was to maintain this term. However, to minimize potential harm resulting from misinterpretations, the panel defined **IUP** as a pregnancy implanted in a normal location. This definition clarifies that pregnancies implanted in abnormal uterine locations, such as the cervix or a cesarean section scar, as well as those transiently located in the lower uterine cavity or endocervical canal in the process of expulsion, are not interpreted as normal in location despite their intra-uterine position. *Normally located pregnancy* and *normally located IUP* are alternate terms.

IUPs are generally close to the midline but can occasionally be somewhat eccentrically located toward the right or left side of the uterus. This can happen in two situations, either of which may lead to diagnostic errors and inappropriate management if inaccurately described. The first is a normal but off-midline implantation in an anatomically normal uterus. These have sometimes been described in the literature as an ‘angular’ or ‘cornual pregnancy’.<sup>41,42</sup> To obviate confusion of this variant with an interstitial EP, these terms as well as the word ‘eccentric’ used in isolation should be avoided; this appearance should simply be reported as an IUP.<sup>43</sup> Alternatively, the user may describe as *eccentrically located GS completely surrounded by endometrium* and conclude as an IUP (Fig 6). Short interval follow-up US or three-dimensional coronal reconstruction may help differentiate from an interstitial EP when uncertain.

The second situation that can lead to a seemingly eccentric IUP is a normally implanted pregnancy within a uterus with a müllerian duct anomaly. In such cases, the location of the sac relative to the anomaly should be described instead of using terms such as ‘cornual,’ ‘bicornuate,’ and ‘unicornuate pregnancy’.<sup>43</sup> Reporting examples include GS



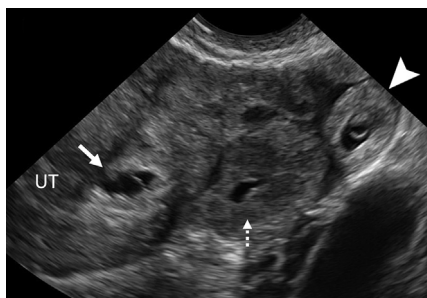
**FIGURE 7****Specific normal and abnormal pregnancy location sites**

Schematic illustration of normal pregnancy implantation sites on the left half of the uterine diagram and abnormal implantation sites on the right. Representative round icons indicate the implantation site with corresponding letters to lexicon terms in the box. Of note, it is optional to further describe a tubal ectopic pregnancy location as *isthmic*, *infundibular*, or *ampullary* when the precise location is clear at US.

**Abnormal: ectopic pregnancy**

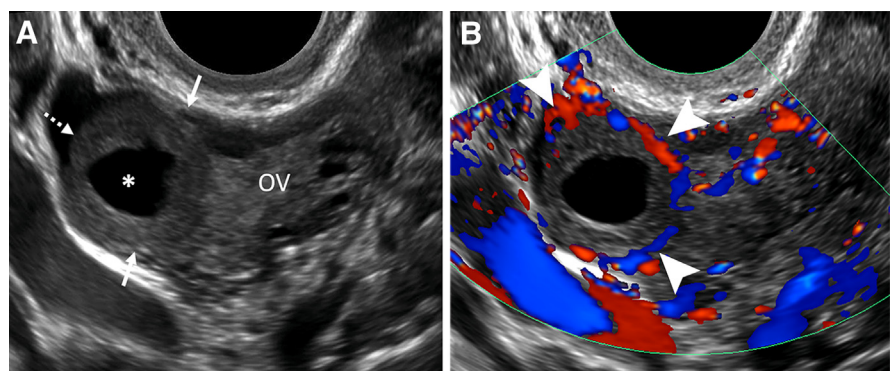
An untreated EP carries a risk of maternal morbidity and mortality. The term **EP** is deeply rooted in the medical literature, as well as the vernacular of patients, and describes a pregnancy that is abnormally located. Its use was unanimously approved by the panel. EP is defined as a pregnancy implanted in an abnormal location, whether intrauterine or extrauterine. This definition differs slightly from the ACOG practice bulletin on tubal EP,<sup>44</sup> which defines an EP as a pregnancy outside the uterine cavity, a definition that does not clearly consider abnormal intrauterine implantations (eg, cesarean scar).

When an EP is described, the location should precede the term **EP** in the report. Ectopic locations include **tubal**, **interstitial**, **cervical**, **cesarean scar**, **ovarian**, **abdominal**, and **intramural** (Fig 7). Though tubal EP locations can be further characterized as *isthmic*, *infundibular*, and *ampullary*, these terms are optional since the precise location of a tubal EP is typically not evident at US. The description of an EP should also include the presence of a yolk sac, embryo, fetus, or cardiac activity when present to assist with

**FIGURE 8****Heterotopic pregnancy**

Transvaginal transverse grayscale US image in a 27-year-old pregnant patient shows an early intrauterine pregnancy (IUP) (solid arrow) containing a yolk sac and a tubal ring of ectopic pregnancy (EP) (arrowhead) also containing a yolk sac. The coexistence of an IUP and EP is termed **heterotopic pregnancy**. The left ovary contains a corpus luteum (dotted arrow) and is seen in the center. The rim of chorionic tissue in the IUP and EP is hyperechoic, whereas in contrast, the corpus luteum is hypoechoic. Echogenicity can help distinguish a tubal ring from a corpus luteum in some cases. UT = uterus.

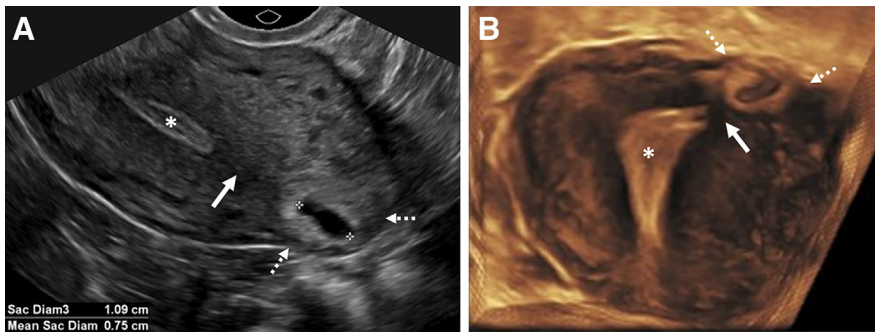
is normally located in the left horn of a bicornuate uterus and GS is normally located in a unicornuate uterus.<sup>43</sup>

**FIGURE 9****Corpus luteum**

(A) Transvaginal sagittal grayscale and (B) color Doppler US image in a 31-year-old pregnant patient shows a round, hypoechoic, thick-walled structure (dotted arrow) with a central cystic space (\*) and peripheral vascularity (arrowheads), characteristic of a **corpus luteum**. This corpus luteum arises in an exophytic fashion from the right ovary (OV), which can mimic a tubal ring of ectopic pregnancy. A helpful feature to diagnose a corpus luteum is a **claw sign** (solid arrows) of partially surrounding ovarian parenchyma, which confirms an ovarian origin.



**FIGURE 10**  
**Interstitial ectopic pregnancy (EP)**



(A) Transvaginal transverse grayscale and (B) coronal reformatted three-dimensional US image in a 29-year-old pregnant patient shows a gestational sac (GS) (calipers) at 5 weeks 3 days. There is intervening myometrium (solid arrow) between the GS and endometrium (\*). A *claw sign* (dotted arrows) of myometrial tissue confirms the pregnancy is implanted in the interstitial (intramyometrial) segment of the tube, termed an *interstitial EP*. The term 'cornual EP' should be avoided. Coronal reformatted three-dimensional US may better demonstrate an interstitial EP separate from the endometrium, as in this case. Diam = diameter.

### Special considerations

**Tubal EP.**— Implantation in the fallopian tube distal to the interstitial segment accounts for the majority of EPs (84%–93%).<sup>46,47</sup> The most frequent observation of a *tubal EP* is an adnexal mass of variable echogenicity and vascularity, separate from the ovary;<sup>48</sup> the term *extraovarian mass* is used for this appearance. *Adnexal mass* is an alternate term that is favored when the ovary is not visualized. The second most common observation is a *tubal ring*, a round or oval fluid collection with a hyperechoic rim (representing the GS) in the adnexa separate from the ovary, with variable peripheral vascularity.<sup>48</sup> Alternate terms for a tubal ring include *adnexal ring* and *adnexal GS*. The descriptors 'blob,' 'bagel,' and 'donut sign' are vernacular terms to avoid. When no IUP is visualized, an extraovarian mass or a tubal ring has a high likelihood of representing a tubal EP.<sup>49</sup>

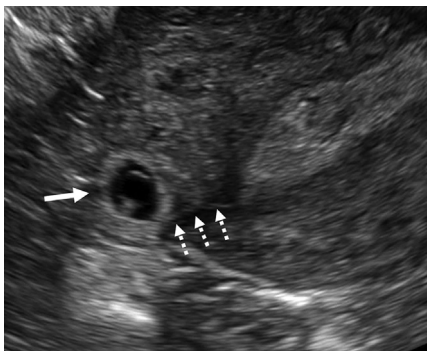
Differentiating an empty tubal ring of an EP from a corpus luteum can be challenging. Because a ring of peripheral vascularity at color Doppler US may occur with both, color flow is not a discriminating feature. Usually, a tubal ring is more echogenic than a corpus luteum.<sup>50</sup> The location completely

treatment planning. It should also describe laterality, when applicable. In most scenarios, an EP should be described as *probable* if there is no yolk sac or embryo and *definite* if a yolk sac

or embryo is present, parallel to the terminology for probable and definite IUP. The terms 'live,' 'living,' and 'viable' should be avoided when describing cardiac activity in an EP.

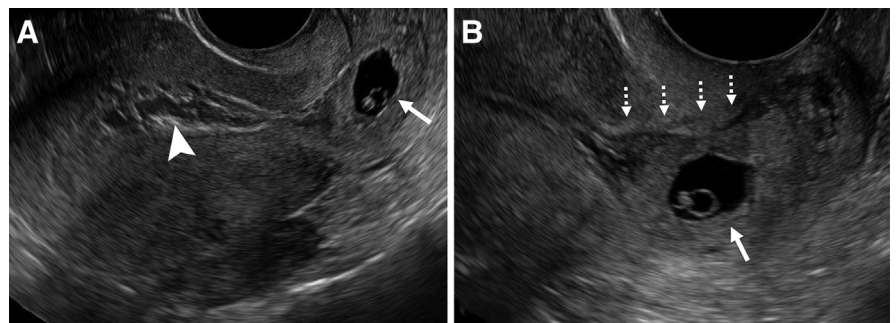
**Heterotopic pregnancy** describes coexistence of an IUP and an EP. While extremely rare, this condition occurs with increased frequency in patients undergoing infertility treatment<sup>45</sup> (Fig 8).

**FIGURE 11**  
**Interstitial line sign**



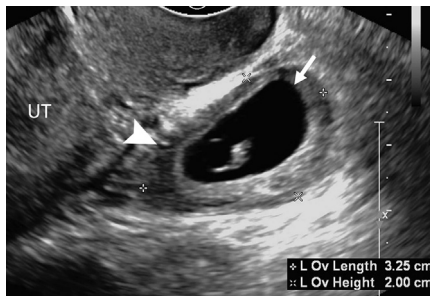
Transvaginal transverse grayscale US image in a 33-year-old pregnant patient shows a right *interstitial ectopic pregnancy* (EP) (solid arrow) at 6 weeks 0 days. In addition to the characteristic sonographic findings of an interstitial EP shown in Figure 10, there is a thin echogenic line (dotted arrows) representing the interstitial segment of the tube. This line connects the endometrium to the ectopic gestational sac and is called the *interstitial line sign*.

**FIGURE 12**  
**Cervical ectopic pregnancy (EP)**



(A) Transvaginal sagittal grayscale US of the uterus and (B) high-resolution US image of the cervix in a 31-year-old pregnant patient at 6 weeks 3 days with vaginal bleeding. A gestational sac (GS) (solid arrow) is seen containing an embryo with cardiac activity (not shown) implanted in the cervix. Mixed-echogenicity material (arrowhead) representing blood products expands the endometrial cavity. The location of the GS eccentric to the endocervical canal (dotted arrows) and cardiac activity help make the diagnosis of a *cervical EP*. The term 'cervical pregnancy' should be avoided.

**FIGURE 13**  
**Ovarian ectopic pregnancy (EP)**



Transvaginal sagittal grayscale US image in a 35-year-old pregnant patient at 6 weeks 4 days shows a gestational sac (GS) (arrow) containing a yolk sac and embryo with cardiac activity (not shown) within the ovary (Ov) (calipers), diagnostic of an *ovarian EP*. A peripheral follicle is present in the ovary (arrowhead). To avoid misdiagnosing a corpus luteum for the rare ovarian EP, a yolk sac or embryo should be present in the intraovarian thick-walled cystic structure representing the GS. UT = uterus.

within the ovary or the presence of a *claw sign*<sup>51</sup> of ovarian tissue around the lesion may help to confirm a corpus luteum (Fig 9). The *sliding sign*,<sup>52</sup> elicited with transvaginal probe pressure, may be helpful to confirm that a mass or tubal ring moves separately from the ovary (Movie).

**Interstitial EP.**— An *interstitial EP* is a rare type of EP in which the pregnancy

implants within the intramyometrial segment of the fallopian tube (Fig 10). Absence of a sliding sign between the uterus and GS, three-dimensional coronal reconstructed image,<sup>53</sup> uterine claw sign of myometrium partially surrounding the GS, or a thin band of myometrium between the endometrium and GS may be helpful in the diagnosis.<sup>43,54</sup> The *interstitial line sign* may be useful but is rarely encountered<sup>55</sup> (Fig 11). The term ‘cornual EP’ should be avoided, since ‘cornual’ has been used indiscriminately to describe both an EP as well as an IUP in one horn of a bicornuate uterus or an IUP in the upper lateral endometrial cavity.

**Cesarean scar EP.**— Implantation of a pregnancy in a cesarean section scar or niche is becoming more common as the rate of cesarean delivery rises worldwide.<sup>56–58</sup> Since implantation at this site carries a high risk of maternal morbidity and mortality, including uterine rupture and complications of placenta accreta spectrum, the term *cesarean scar EP* should be used in lieu of ‘cesarean scar pregnancy.’ This is in accordance with recommendations of the Society for Maternal-Fetal Medicine.<sup>59</sup>

A GS in this location can mimic a cervical EP and a pregnancy in the process of passing. The reader is referred to the medical literature for diagnostic criteria to differentiate cesarean scar

EP<sup>60–63</sup> from a cervical EP and a passing GS.<sup>64,65</sup>

**Cervical EP.**— A pregnancy implanted in the endocervical mucosa is termed a *cervical EP* (Fig 12). The term ‘cervical pregnancy’ should be avoided.

**Ovarian EP.**— A pregnancy in or on an ovary is termed an *ovarian EP*. Ovarian EP is exceedingly rare and presents diagnostic challenges, as it often mimics a corpus luteum. Because the overwhelming majority of intraovarian thick-walled cysts represent a corpus luteum, the diagnosis of ovarian EP should not be made unless a yolk sac, embryo, or cardiac activity is definitely seen in the intraovarian lesion (Fig 13).

### **Unknown: pregnancy of unknown location**

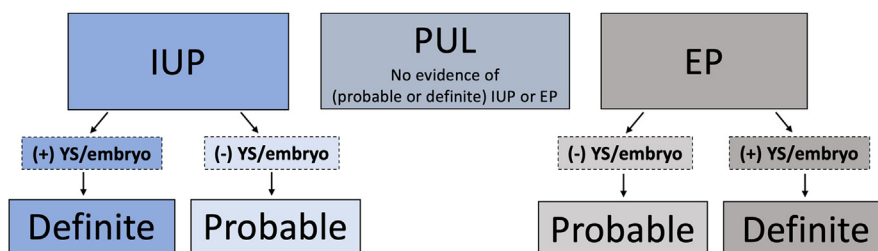
A *pregnancy of unknown location* (PUL) is the terminology used as a diagnostic placeholder when the transvaginal US examination of a patient with a positive hCG shows neither an IUP nor EP.<sup>2,66</sup> As most IUPs will be seen with transvaginal US when hCG is 3000 mIU/mL or higher, the differential diagnosis of a PUL with a lower hCG includes (a) nonvisualized early IUP, (b) nonvisualized EP, or (c) an early pregnancy loss that has completely passed.<sup>2,3,67</sup> Correlation with trending hCG values and follow-up US is helpful to differentiate these scenarios.<sup>3,67</sup>

Some authors have altered the original definition of PUL to mean no sonographic findings of a definite IUP or EP.<sup>44</sup> However, this modified definition creates uncertainty when a likely diagnosis, such as a *probable IUP* or *probable EP*, is favored. The consensus is to use the original definition whereby any signs of an IUP or EP, *probable* or *definite*, would not qualify as a PUL (Fig 14).

### **Early Pregnancy Loss**

In 2013, sonographic criteria to diagnose first-trimester pregnancies that will not progress were established by an SRU consensus panel.<sup>3</sup> That article used the

**FIGURE 14**  
**Pregnancy of unknown location (PUL)**


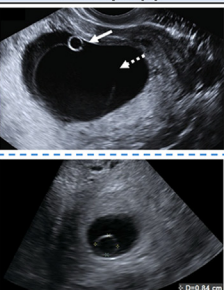
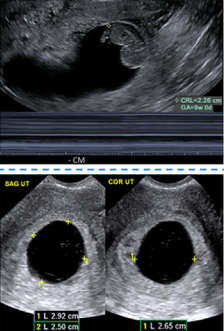

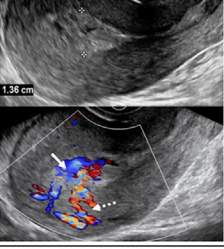
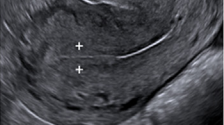
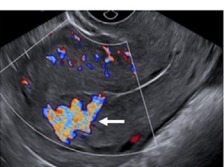


IUP = intrauterine pregnancy; PUL = pregnancy of unknown location; EP = ectopic pregnancy; YS = yolk sac

The original definition of PUL is maintained; however, it is clarified in the lexicon to clearly state that there should be no evidence of *probable* or *definite* intrauterine pregnancy (IUP) or ectopic pregnancy (EP) to qualify as a PUL. An empty gestational sac is considered a *probable* pregnancy whether implanted in a normal location (IUP) or abnormal location (EP) and should not be termed a PUL.



**FIGURE 15**  
**Early pregnancy loss (EPL)**

 <b>SRU FIRST TRIMESTER ULTRASOUND LEXICON: EARLY PREGNANCY LOSS (EPL)</b>					
Term(s) Alternate Term(s)	Image Example(s)	Image Key	Definitions/ Applications	Term(s) to Avoid	Comments
<b>Concerning for EPL</b>  Concerning for miscarriage  Concerning for spontaneous abortion (SAB)  IUP of unknown prognosis		Solid arrow = YS  Dotted arrow = amnion  Calipers = YS  (YS = 8 mm)	Normally located GS with findings that suggest a pregnancy may not progress	'Failure'  'IUP of uncertain viability'	<ul style="list-style-type: none"> <li>Criteria* on TVUS are as follows:               <ul style="list-style-type: none"> <li>Embryonic CRL &lt;7 mm and no cardiac activity</li> <li>MSD 16-24 mm and no embryo</li> <li>Absence of embryo with cardiac activity 7-13 days following visualized GS and no YS</li> <li>Absence of embryo with cardiac activity 7-10 days following visualized GS with YS</li> <li>Empty amnion sign</li> <li>Enlarged YS (&gt;7 mm)</li> <li>Small GS relative to embryo (typically subjective; optional formula: MSD - CRL = &lt;5)</li> <li>Absent embryo ≥6 weeks after LMP</li> </ul> </li> <li>Refer to literature for other poor prognosticators</li> </ul>
<b>Diagnostic of EPL</b>  Diagnostic of miscarriage  Diagnostic of SAB  <u>Special scenarios:</u>  Embryonic/fetal demise  Anembryonic pregnancy		Calipers = embryo  (CRL = 23 mm; No cardiac motion)  Calipers = MSD  (MSD = 27 mm)	Normally located GS with findings definitive for a pregnancy that will not progress	'Failure'  'Blighted ovum'  'Nonviable'  'Nonviability'	<ul style="list-style-type: none"> <li>Criteria* on TVUS are as follows:               <ul style="list-style-type: none"> <li>CRL ≥7 mm and no cardiac activity</li> <li>MSD ≥25 mm and no embryo</li> <li>Absence of embryo with cardiac activity ≥14 days after visualization of GS and no YS</li> <li>Absence of embryo with cardiac activity ≥11 days after visualization of GS with YS</li> </ul> </li> <li>Optional terms for special scenarios:               <ul style="list-style-type: none"> <li><b>Embryonic/fetal demise</b> = CRL ≥7 mm and no cardiac activity (fetal when GA ≥11 weeks 0 days)</li> <li><b>Anembryonic pregnancy</b> = no embryo and 1 of the following:                   <ul style="list-style-type: none"> <li>MSD ≥25 mm</li> <li>≥14 days since US showing GS and no YS</li> <li>≥11 days since US showing GS with YS</li> </ul> </li> </ul> </li> </ul>
<b>EPL in progress</b>  Miscarriage in progress  SAB in progress		Arrow = embryo in LUS/upper cervix  (No CM)	GS located in cavity of lower uterine segment or endocervical canal in process of expulsion		<ul style="list-style-type: none"> <li>If cardiac activity present, consider cervical or cesarean scar ectopic pregnancy</li> <li>Color Doppler, <b>sliding sign</b> on TVUS or short-interval follow-up US may be helpful in uncertain cases</li> </ul>
<b>Incomplete EPL</b>  Retained (or residual) products of conception (RPOC)  Incomplete Miscarriage/SAB  Description of findings in lieu of term		Calipers = endometrial thickness (ET = 14 mm)  Solid arrow = RPOC  Dotted arrow = EMV	Residual intracavitary tissue or thickened endometrium following EPL, typically with internal vascularity; ± persistent GS	'Embryonic tissue'  'Fetal tissue'	<ul style="list-style-type: none"> <li>Option to substitute <b>residual</b> for <b>retained</b> as tissue may spontaneously expel and retained may imply tissue is fixed prompting unnecessary intervention; treatment is based on clinical factors or persistent GS               <ul style="list-style-type: none"> <li>If GS in lower uterine segment/endocervix, see EPL in progress above</li> </ul> </li> <li>Vascular flow in endometrial cavity confirms tissue</li> <li>Endometrium &lt;10 mm without vascular flow is unlikely to represent incomplete EPL</li> <li>Enhanced myometrial vascularity (EMV) typically seen</li> </ul>
<b>Completed EPL</b>  Completed miscarriage  Completed SAB		Calipers = endometrial thickness  (ET = 7 mm)	No intracavitary tissue or persistent GS following EPL		<ul style="list-style-type: none"> <li>Used in following scenarios:               <ul style="list-style-type: none"> <li>Prior visualized GS that is no longer seen and no residual intracavitary tissue</li> <li>In differential diagnosis of pregnancy of unknown location (PUL)</li> </ul> </li> </ul>
<b>- Enhanced myometrial vascularity (EMV)</b>		Arrow = EMV	Focal myometrial vascularity deep to prior pregnancy implantation site		<ul style="list-style-type: none"> <li>Transient/expected finding following EPL (incomplete or completed); typically, resolves spontaneously</li> <li>Should <b>NOT</b> be confused with:               <ul style="list-style-type: none"> <li>Arterio-venous fistula (AVF): rare; most commonly due to sharp curettage</li> <li>Arterio-venous malformation (AVM): rare; congenital anomaly</li> <li>Subinvolution of the placental site (SIPS): pathologic diagnosis</li> </ul> </li> </ul>

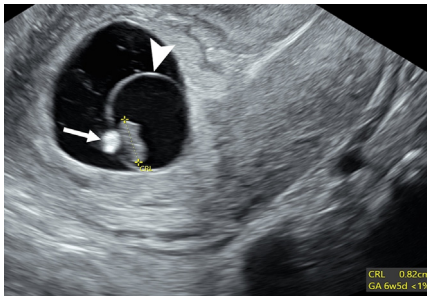
SRU = Society of Radiologist in Ultrasound; IUP = intrauterine pregnancy; cm = centimeters; YS = yolk sac; GS = gestational sac; \*Doubilet et al. NEJM 2013, PMID 24106937, DOI 10.1056/NEJMr1302417; TVUS = transvaginal US; MSD = mean sac diameter; CRL = crown-rump length; LMP = last menstrual period; GA = gestational age; CM = cardiac motion; SAG = sagittal; COR = coronal; "±" = with or without; ET = endometrial thickness

There are five main categories of EPL: concerning for, diagnostic of, in progress, incomplete, and completed. Enhanced myometrial vascularity (EMV) is included in the lexicon since increased myometrial vascularity deep to a prior implantation site is commonly confused with other rare entities, such as an arteriovenous fistula and arteriovenous malformation, which may lead to unnecessary work-up.



**FIGURE 16**

**Poor prognosticators: calcified yolk sac and expanded amnion sign**



Transvaginal sagittal grayscale US image in a 27-year-old pregnant patient shows an 8-mm embryo (calipers) without cardiac activity (M-mode not shown) sufficient for the interpretation of diagnostic of EPL. Additional poor prognosticators include a calcified yolk sac (arrow) and an enlarged amniotic cavity (arrowhead) relative to the crown-rump length (CRL) of the embryo, called the expanded amnion sign. These additional observations, on their own, are only concerning for EPL. GA = gestational age.

terms ‘suspicious for’ and ‘diagnostic of pregnancy failure’ to describe pregnancies that are unlikely to progress or will definitely not progress, respectively. These terms are widely used by radiologists. In 2018, an ACOG practice bulletin used the term *early pregnancy loss* (EPL) to describe a spectrum of scenarios in the first trimester, including those meeting SRU criteria for ‘failure,’ noting that *spontaneous abortion* and *miscarriage* could be used interchangeably.<sup>7</sup> Contemporaneously, a survey found that patients associated the term ‘failure’ with fault, blame, and inadequacy and preferred the term *miscarriage*.<sup>68</sup> Therefore, we aimed to establish pan-specialty terminology that would be clear, specific, and patient-centric. The 2013 SRU Consensus Panel diagnostic criteria remain unaltered for the purposes of this lexicon, though we acknowledge that additional literature continues to emerge.

There are five categories in this scenario: (a) IUP with findings that suggest the pregnancy may not progress, (b) IUP with findings that the pregnancy will

definitely not progress, (c) GS in the lower endometrial cavity or endocervical canal in the process of expulsion, (d) residual pregnancy tissue or persistent GS, and (e) complete passage of the GS without residual tissue. To keep the number of terms to a minimum and facilitate widespread acceptance, the panel adopted **EPL** as the central term in conjunction with modifiers that describe these five categories (Fig 15). The alternate terms *miscarriage* or *spontaneous abortion* may substitute for EPL in these phrases. For *spontaneous abortion*, the panel suggests consideration of a statement in the report that *spontaneous abortion* is synonymous with *miscarriage*, thereby providing greater clarity for patients.

### Concerning for EPL

**Concerning for EPL** replaces ‘suspicious for pregnancy failure.’ *Concerning* is a more compassionate and less ominous term than ‘suspicious.’ An alternative term is *IUP of uncertain prognosis*, which replaces the phrase ‘IUP of uncertain viability.’ Poor prognostic findings other than those established in the 2013 SRU consensus exist, such as a calcified yolk sac and expanded amnion sign, and the literature should be referenced for these terms (Fig 16).<sup>69–71</sup>

### Diagnostic of EPL

**Diagnostic of EPL** replaces ‘diagnostic of pregnancy failure.’ Other terms to avoid include ‘blighted ovum’ and ‘nonviable pregnancy.’ **Embryonic demise** refers to a specific scenario in this category when the crown-rump length is 7 mm or longer and there is absence of cardiac activity; **fetal demise** is used with a GA of 11 weeks 0 days or more. **Anembryonic pregnancy** is a specific term for a GS measuring 25 mm or larger without an embryo, or absence of an embryo on serial examinations obtained at discriminatory time intervals.<sup>3</sup>

### EPL in progress

**EPL in progress** describes the situation in which the GS is located in the endometrial cavity within the lower uterine


segment or the endocervical canal and is in the process of expulsion. If cardiac activity is present, one should consider the diagnosis of cervical EP or cesarean scar EP. Movement of a sac, either spontaneously or with uterine pressure from the US probe (*sliding sign*),<sup>52,64</sup> may be used to confirm that it is not implanted but transiently located in the lower uterus, favoring an EPL in progress. Focal vascularity at color Doppler US at the myometrial-endometrial junction more superiorly in the uterus indicates this location as the implantation site. Short interval follow-up imaging is recommended in indeterminate cases.

### Incomplete EPL

**Incomplete EPL** is defined as the presence of intracavitary tissue, typically with internal vascularity, or a persistent GS following an EPL and is the panel’s preferred term. Alternate terms include *retained products of conception* (RPOC) or concluding with a description of the observations from the findings section of the report, such as *thickened endometrium with vascularity*,<sup>72</sup> in lieu of a term. Some panelists strongly suggested removing “retained” in RPOC, as it may imply the tissue is fixed, leading to unnecessary intervention, while the decision to treat is based on clinical factors or a persistent GS.<sup>73–75</sup> However, given that RPOC is used in all trimesters and relays useful information to pathologists when provided as the clinical indication for histologic evaluation, removing “retained” may pose unforeseen challenges. *Residual* may be a softer adjective to “retained,” possibly decreasing the implication that tissue is fixed. Therefore, *residual products of conception* is another alternate phrase in this lexicon preserving the acronym RPOC, which is in common use. It is important to note in making the diagnosis, an endometrial thickness less than 10 mm has a high negative predictive value for incomplete EPL, while vascular flow in the endometrial cavity increases the likelihood that tissue is present.<sup>76,77</sup> Terms to avoid in

FIGURE 17

## Summary of major lexicon changes highlighting terms to use

 <b>SUMMARY OF MAJOR LEXICON CHANGES: TERMS TO USE</b>	
Terms to Use	Comments
<b>Early Pregnancy Loss (EPL)</b>	<ul style="list-style-type: none"> <li>General term endorsed by OB-Gyn communities and societies to describe a pregnancy that may or will not progress, is in the process of expulsion, or has incompletely or completely passed; replaces 'failure'</li> <li>Modifiers to differentiate above scenarios are as follows:               <ul style="list-style-type: none"> <li><b>Concerning for</b> = GS normally located but with findings that it may not progress</li> <li><b>Diagnostic of</b> = GS normally located but with findings that it will not progress</li> <li><b>In progress</b> = GS located in cavity of LUS or endocervical canal in process of expulsion</li> <li><b>Incomplete</b> = Intracavitary tissue, thickened endometrium or persistent GS following EPL                   <ul style="list-style-type: none"> <li>Alternate terms:                       <ul style="list-style-type: none"> <li><i>Retained (or residual) products of conception (RPOC)</i></li> <li>Description of findings in lieu of a term (e.g., <i>intracavitary vascularized tissue</i>, etc.)</li> </ul> </li> </ul> </li> <li><b>Completed</b> = No persistent GS or intracavitary tissue following EPL</li> </ul> </li> <li>Alternate terms for EPL to be used along with above modifiers:               <ul style="list-style-type: none"> <li><i>Miscarriage</i> <ul style="list-style-type: none"> <li>Preferred by patients in one survey</li> </ul> </li> <li><i>Spontaneous abortion in progress (SAB)</i> <ul style="list-style-type: none"> <li>If using, consider reporting as synonymous with miscarriage for patient clarity</li> </ul> </li> </ul> </li> </ul>
<b>Cardiac activity</b>	<ul style="list-style-type: none"> <li>Term for embryonic/fetal rhythmic pulsations; replaces 'heart', 'heart motion', 'heartbeat', etc.</li> <li>Alternate term: <i>cardiac motion</i></li> <li>Avoid the terms 'live', 'living' and 'viable' in the 1<sup>st</sup> trimester</li> </ul>
<b>Ectopic Pregnancy</b>	<ul style="list-style-type: none"> <li>Defined as a pregnancy <u>implanted</u> in an abnormal location, whether extrauterine or intrauterine               <ul style="list-style-type: none"> <li>Clarifies cervical and Cesarean scar sites as ectopic pregnancies</li> </ul> </li> <li>Use <b>probable</b> if no YS or embryo seen</li> <li>Use <b>definite</b> if YS or embryo seen</li> </ul>

OB-Gyn = Obstetrical and Gynecologic; GS = gestational sac; LUS = lower uterine segment; YS = yolk sac; 1<sup>st</sup> = first

The major changes from currently used terminology to describe sonographic findings in the first trimester are (a) *early pregnancy loss* in lieu of 'failure'; (b) *cardiac activity* in lieu of 'heart motion'; and (c) defining *ectopic pregnancy* as an abnormal implantation site. The terms 'live,' 'living,' and 'viable' are commonly used terms to describe cardiac activity. However, as these terms may be misleading, they are best avoided in the first trimester.

this setting include intracavitary 'embryonic tissue' and 'fetal tissue.'

### Completed EPL

**Completed EPL** refers to complete passage of the GS and chorionic tissue from the uterus following an EPL. This term may be used with certainty when accompanied by an earlier US examination with a documented GS or in the differential diagnosis of a PUL.

Another term included in the EPL subset is **enhanced myometrial vascularity**, used to describe the typically transient and physiologic finding of focal myometrial vascularity deep to a prior pregnancy implantation site. In the first trimester, this can occur following an

incomplete or completed EPL.<sup>78</sup> This entity should not be confused with an arteriovenous fistula, a rare complication of sharp curettage, or arteriovenous malformation, a rare congenital anomaly.<sup>79–81</sup> The term "subinvolution of the placental site" is a pathologic diagnosis, which is beyond the scope of this lexicon.<sup>82,83</sup>

### Conclusion

The medical terminology related to first-trimester US is relatively new, as it is based on a technology that came of age in the latter half of the 20th century. Just as advances in transvaginal US have helped revolutionize the care of obstetric patients, the terminology used for optimal interpretation and

communication must continue to evolve in a consistent and well-defined manner.

Thus, in developing this lexicon, our recommendations include terms to use (Fig 17) as well as terms to avoid (Fig 18). Outdated and confusing terms such as 'fetal pole,' 'pseudosac,' and 'angular pregnancy' should be abandoned. The term 'pregnancy failure' is often felt by patients to be hurtful and accusatory. **EPL** is thus recommended in its place, together with the following modifiers: **concerning for**, **diagnostic of**, **in progress**, **incomplete**, and **completed**. The criteria for making these diagnoses are well-established, with no recommendations for change by our multispecialty group, although

FIGURE 18

## Summary of major lexicon changes highlights terms to avoid



## SUMMARY OF MAJOR LEXICON CHANGES: TERMS TO AVOID

Terms to Avoid	Lexicon Terms
Embryonic 'pole' or fetal 'pole'	<b><i>Embryo</i></b> or <b><i>fetus</i></b>
'Heart', 'heartbeat', 'heart motion', etc.	<b><i>Cardiac activity</i></b> OR <i>cardiac motion</i>
'Live', 'living', 'viable'	<b><i>Cardiac activity</i></b> OR <i>cardiac motion</i>
'Viability' scan	<b><i>First trimester US exam</i></b>
'IUP of uncertain viability'	<b><i>IUP of uncertain prognosis</i></b> OR <b><i>concerning for EPL</i></b>
'Failure'	<b><i>Early pregnancy loss (EPL)</i></b>
'Blighted ovum'	<b><i>Anembryonic pregnancy</i></b> OR <b><i>diagnostic of EPL</i></b>
'Pseudogestational sac', 'pseudosac'	<b><i>Intracavitary fluid</i></b> OR <i>endometrial cavity fluid</i>
'Cesarean scar pregnancy'	<b><i>Cesarean scar ectopic pregnancy</i></b>
'Cervical pregnancy'	<b><i>Cervical ectopic pregnancy</i></b>
'Angular pregnancy', 'cornual pregnancy', 'eccentric pregnancy'	<b><i>IUP</i></b> OR if describing, use: <i>eccentrically located GS completely surrounded by endometrium</i> (and conclude as IUP)
'Cornual ectopic pregnancy'	<b><i>Interstitial ectopic pregnancy</i></b>
'Unicornuate pregnancy', 'bicornuate pregnancy'	Describe GS relative to uterine MDA (e.g., <i>GS in right horn of septate uterus</i> )

US = ultrasound; IUP = intrauterine pregnancy; EPL = early pregnancy loss; GS = gestational sac; MDA = Müllerian duct anomaly

Equally important as terms to use are those terms that are best avoided since they are obsolete or confusing (single quotation marks). This is accompanied by recommended lexicon terms (bold and italicized) to use instead.

we acknowledge the possibility of change as new literature emerges. Cardiac activity replaces 'heart motion' and 'heartbeat' in the first trimester, and 'live,' 'living,' and 'viable' should also be avoided.

EP is defined as a pregnancy implantation in any abnormal location, clarifying pregnancy in the cesarean scar site as an EP. This change aligns with the Society for Maternal-Fetal Medicine endorsement of *cesarean scar EP* due to the high maternal morbidity and mortality associated with allowing such a pregnancy to proceed. The original definition of *PUL* should be maintained as a pregnancy with no transvaginal US findings of IUP or EP, whether *definite* or *probable*. US findings of a *probable IUP* or a *probable EP* should not be interpreted as a *PUL*, since this may lead to inappropriate management.

Our goal was to establish clear, logical, and respectful terminology to be used for diagnosis and management of first- trimester pregnancy. It is our

hope that this lexicon will be widely adopted as all members of the multi-specialty team who treat obstetric patients become familiar with the new terminology. We acknowledge the work of multiple societies and prior consensus panels and foresee future modifications as technology and clinical management evolve. ■

## ACKNOWLEDGMENTS

The panel acknowledges Andrew Phelps, MD, from Oregon Health & Science University School of Medicine, Department of Diagnostic Radiology, for his contributions toward the illustration in Figure 7. The panel also acknowledges Lori Strachowski, MD, for her efforts in creating Figures 1, 2, 5, 7, 14, 15, 17, and 18.

## AUTHOR CONTRIBUTIONS

Guarantors of integrity of entire study, **S.K.R., M.M.H., A. Kamaya, A. Koyama, S.G.O., R.S., L.M.S.**; study concepts/study design or data acquisition or data analysis/interpretation, all authors; manuscript drafting or manuscript revision for important intellectual content, all authors; approval of final version of submitted manuscript, all authors; agrees to ensure any

questions related to the work are appropriately resolved, all authors; literature research, **S.K.R., M.M.H., P.M.D., M.C.F., A. Kennedy, R.A., K.B., L.D., S.K.H., P.C.L., K.E.M., T.M., S.G.O., K.O., R.S., S.S., L.M.S.**; clinical studies, **A. Kennedy, L.D., P.C.L., S.S.**; and manuscript editing, all authors

## DISCLOSURES OF CONFLICTS OF INTEREST

**S.K.R.** Book royalties from Elsevier. **M.M.H.** Payment for lectures, travel, or visiting professorship from Massachusetts General Hospital/Brigham Women's Hospital, University of Toronto, McMaster University, World Class CME, and Hoag Medical Group; section editor for RadioGraphics. **P.M.D.** No relevant relationships. **M.C.F.** Payment for panel discussion from GE Healthcare. **A. Kennedy** Royalties and writer's fees from Elsevier; honoraria from World Class CME and University of California Davis; support for travel from the RSNA; secretary of the Society of Radiologists in Ultrasound. **R.A.** No relevant relationships. **K.B.** Patents planned, issued, or pending with Kristyn Brandi MD MPH LLC. **L.D.** No relevant relationships. **S.K.H.** Grants from the National Center for Advancing Translational Sciences at the National Institutes of Health; payment for presentations from Organon; payment for expert testimony from Huff Powell Bailey; support for attending meeting from the American College of Obstetricians and Gynecologists (ACOG); section



secretary of the Pennsylvania ACOG. **A. Kamaya** Book royalties from Elsevier. **A. Koyama** No relevant relationships. **P.C.L.** Honoraria for editor role from RoshReview (now Blueprint); support to attend meeting from Individuals with Intellectual or Development Disability Engaged, Aligned and Leading project workgroup funded by the Patient-Centered Outcomes Research Institute; secretary-treasurer of the New York Chapter of the American College of Emergency Physicians and past chair of the American College of Emergency Physicians Emergency Ultrasound Section. **K.E.M.** No relevant relationships. **T.M.** Book royalties from Elsevier. **S.G.O.** No relevant relationships. **K.O.** No relevant relationships. **R.S.** Honoraria and support for travel to meetings from World Class CME. **S.S.** Grants from the National Institutes of Health, AbbVie, and Organon. **L.M.S.** No relevant relationships.

## REFERENCES

1. AIUM practice parameter for the performance of standard diagnostic obstetric ultrasound. *J Ultrasound Med* 2024;43(6):E20–32.
2. Barnhart K, van Mello NM, Bourne T, et al. Pregnancy of unknown location: a consensus statement of nomenclature, definitions, and outcome. *Fertil Steril* 2011;95(3):857–66.
3. Doubilet PM, Benson CB, Bourne T, et al. Society of Radiologists in Ultrasound Multi-specialty Panel on Early First Trimester Diagnosis of Miscarriage and Exclusion of a Viable Intrauterine Pregnancy. Diagnostic criteria for nonviable pregnancy early in the first trimester. *N Engl J Med* 2013;369(15):1443–51.
4. Kolte AM, Bernardi LA, Christiansen OB, et al. ESHRE Special Interest Group, Early Pregnancy. Terminology for pregnancy loss prior to viability: a consensus statement from the ESHRE early pregnancy special interest group. *Hum Reprod* 2015;30(3):495–8.
5. Kirk E, Ankum P, Jakab A, et al. ESHRE Working Group on Ectopic Pregnancy. Terminology for describing normally sited and ectopic pregnancies on ultrasound: ESHRE recommendations for good practice. *Hum Reprod Open* 2020;2020(4):a055.
6. ACOG Guide to Language and Abortion. American College of Obstetricians and Gynecology. Published 2023. <https://www.acog.org/-/media/project/acog/acogorg/files/pdfs/publications/abortion-language-guide.pdf>. Accessed December 23, 2023.
7. Prager S, Dalton VK, Allen RH. ACOG Practice Bulletin No. 200: Early Pregnancy Loss. *Obstet Gynecol* 2018;132(5):e197–207.
8. Dobbs v Jackson Women's Health Organization, 97 US (2022). Published 2022. [https://www.supremecourt.gov/opinions/21pdf/19-1392\\_6j37.pdf](https://www.supremecourt.gov/opinions/21pdf/19-1392_6j37.pdf). Accessed December 23, 2023.
9. Frederick-Dyer K, Andreotti R, Cooke E, et al. Patient-centered care: radiologists advocate to protect the patient-physician relationship. *J Am Coll Radiol* 2023;20(9):936–9.
10. Diamond IR, Grant RC, Feldman BM, et al. Defining consensus: a systematic review recommends methodologic criteria for reporting of Delphi studies. *J Clin Epidemiol* 2014;67(4):401–9.
11. Nasa P, Jain R, Juneja D. Delphi methodology in healthcare research: how to decide its appropriateness. *World J Methodol* 2021;11(4):116–29.
12. Jünger S, Payne SA, Brine J, Radbruch L, Brearley SG. Guidance on Conducting and REporting DElphi Studies (CREDES) in palliative care: recommendations based on a methodological systematic review. *Palliat Med* 2017;31(8):684–706.
13. Cole LA, DuToit S, Higgins TN. Total hCG tests. *Clin Chim Acta* 2011;412(23-24):2216–22.
14. Cole LA. The hCG assay or pregnancy test. *Clin Chem Lab Med* 2012;50(4):617–30.
15. Stenman UH, Alfthan H, Ranta T, Vartiainen E, Jalkanen J, Seppälä M. Serum levels of human chorionic gonadotropin in nonpregnant women and men are modulated by gonadotropin-releasing hormone and sex steroids. *J Clin Endocrinol Metab* 1987;64(4):730–6.
16. Committee Opinion No 700. Methods for Estimating the Due Date. *Obstet Gynecol* 2017;129:e150–4.
17. Curran MA. Fetal Development. Perinatology. Updated January 2, 2023. <https://perinatology.com/Reference/Fetal%20development.htm>. Accessed August 29, 2023.
18. Jha P, Morgan TA, Kennedy A. US evaluation of twin pregnancies: importance of chorionicity and amnionity. *RadioGraphics* 2019;39(7):2146–66.
19. Bree RL, Edwards M, Böhm-Vélez M, Beyler S, Roberts J, Mendelson EB. Transvaginal sonography in the evaluation of normal early pregnancy: correlation with HCG level. *AJR Am J Roentgenol* 1989;153(1):75–9.
20. Goldstein I, Zimmer EA, Tamir A, Peretz BA, Paldi E. Evaluation of normal gestational sac growth: appearance of embryonic heartbeat and embryo body movements using the transvaginal technique. *Obstet Gynecol* 1991;77(6):885–8.
21. Parvey HR, Dubinsky TJ, Johnston DA, Maklad NF. The chorionic rim and low-impedance intrauterine arterial flow in the diagnosis of early intrauterine pregnancy: evaluation of efficacy. *AJR Am J Roentgenol* 1996;167(6):1479–85.
22. Nyberg DA, Mack LA, Harvey D, Wang K. Value of the yolk sac in evaluating early pregnancies. *J Ultrasound Med* 1988;7(3):129–35.
23. Lindsay DJ, Lovett IS, Lyons EA, et al. Yolk sac diameter and shape at endovaginal US: predictors of pregnancy outcome in the first trimester. *Radiology* 1992;183(1):115–8.
24. Detti L, Roman RA, Goedecke PJ, et al. Pilot study establishing a nomogram of yolk sac growth during the first trimester of pregnancy. *J Obstet Gynaecol Res* 2020;46(2):223–8.
25. Phillips CH, Benson CB, Durfee SM, Heller HT, Doubilet PM. "Pseudogestational sac" and other 1980s-era concepts in early first-trimester ultrasound: are they still relevant today? *J Ultrasound Med* 2020;39(8):1547–51.
26. Doubilet PM, Benson CB. First, do no harm... to early pregnancies. *J Ultrasound Med* 2010;29(5):685–9.
27. Lee IT, Rubin ES, Wu J, Koelper N, Barnhart KT. The incidence and importance of the pseudogestational sac revisited. *Am J Obstet Gynecol* 2022;226(4):537.e1–7.
28. Richardson A, Gallos I, Dobson S, Campbell BK, Coomarasamy A, Raine-Fenning N. Accuracy of first-trimester ultrasound in diagnosis of intrauterine pregnancy prior to visualization of the yolk sac: a systematic review and meta-analysis. *Ultrasound Obstet Gynecol* 2015;46(2):142–9.
29. Yeh HC, Goodman JD, Carr L, Rabinowitz JG. Intradecidual sign: a US criterion of early intrauterine pregnancy. *Radiology* 1986;161(2):463–7.
30. Laing FC, Brown DL, Price JF, Teeger S, Wong ML. Intradecidual sign: is it effective in diagnosis of an early intrauterine pregnancy? *Radiology* 1997;204(3):655–60.
31. Chiang G, Levine D, Swire M, McNamara A, Mehta T. The intradecidual sign: is it reliable for diagnosis of early intrauterine pregnancy? *AJR Am J Roentgenol* 2004;183(3):725–31.
32. Bradley WG, Fiske CE, Filly RA. The double sac sign of early intrauterine pregnancy: use in exclusion of ectopic pregnancy. *Radiology* 1982;143(1):223–6.
33. Doubilet PM, Benson CB. Double sac sign and intradecidual sign in early pregnancy: interobserver reliability and frequency of occurrence. *J Ultrasound Med* 2013;32(7):1207–14.
34. Marks WM, Filly RA, Callen PW, Laing FC. The decidual cast of ectopic pregnancy: a confusing ultrasonographic appearance. *Radiology* 1979;133(2):451–4.
35. Nyberg DA, Laing FC, Filly RA, Uri-Simmons M, Jeffrey RB Jr. Ultrasonographic differentiation of the gestational sac of early intrauterine pregnancy from the pseudogestational sac of ectopic pregnancy. *Radiology* 1983;146(3):755–9.
36. Hill MA. Early human development. *Clin Obstet Gynecol* 2007;50(1):2–9. <http://journals.lww.com/clinicalobgyn>.
37. Hill MA. Embryology Carnegie stage 23. Updated February 26, 2022. [https://embryology.med.unsw.edu.au/embryology/index.php/Carnegie\\_stage\\_23](https://embryology.med.unsw.edu.au/embryology/index.php/Carnegie_stage_23). Accessed August 29, 2023.
38. Sylva M, van den Hoff MJB, Moorman AFM. Development of the human heart. *Am J Med Genet A* 2014;164A(6):1347–71.
39. Pettker CM, Turrentine MA, Simhan HN. The limits of viability. *Obstet Gynecol* 2023;142(3):725–6.

40. Yeh HC, Rabinowitz JG. Amniotic sac development: ultrasound features of early pregnancy—the double bleb sign. *Radiology* 1988;166(1 Pt 1):97–103.
41. Jansen RP, Elliott PM. Angular intrauterine pregnancy. *Obstet Gynecol* 1981;58(2):167–75.
42. Finlinson AR, Bollig KJ, Schust DJ. Differentiating pregnancies near the uterotubal junction (angular, cornual, and interstitial): a review and recommendations. *Fertil Res Pract* 2020;6(1):8.
43. Baltarowich OH. The term “cornual pregnancy” should be abandoned. *J Ultrasound Med* 2017;36(6):1081–7.
44. Barnhart KT, Franasiak JM; Committee on Practice Bulletins-Gynecology. ACOG Practice Bulletin No. 193: Tubal Ectopic Pregnancy. *Obstet Gynecol* 2018;131(3):e91–103.
45. Talbot K, Simpson R, Price N, Jackson SR. Heterotopic pregnancy. *J Obstet Gynaecol* 2011;31(1):7–12.
46. Tang P, Li X, Li W, Li Y, Zhang Y, Yang Y. The trend of the distribution of ectopic pregnancy sites and the clinical characteristics of caesarean scar pregnancy. *Reprod Health* 2022;19(1):182.
47. Bouyer J, Coste J, Fernandez H, Pouly JL, Job-Spira N. Sites of ectopic pregnancy: a 10 year population-based study of 1800 cases. *Hum Reprod* 2002;17(12):3224–30.
48. Frates MC, Doubilet PM, Peters HE, Benson CB. Adnexal sonographic findings in ectopic pregnancy and their correlation with tubal rupture and human chorionic gonadotropin levels. *J Ultrasound Med* 2014;33(4):697–703.
49. Brown DL, Doubilet PM. Transvaginal sonography for diagnosing ectopic pregnancy: positivity criteria and performance characteristics. *J Ultrasound Med* 1994;13(4):259–66.
50. Stein MW, Ricci ZJ, Novak L, Roberts JH, Koenigsberg M. Sonographic comparison of the tubal ring of ectopic pregnancy with the corpus luteum. *J Ultrasound Med* 2004;23(1):57–62.
51. Yudin A. Spur, Claw, or Beak Sign. In: *Metaphorical Signs in Computed Tomography*. Springer; 2023. p.159.
52. Timor-Tritsch IE. Sliding organs sign in gynecological ultrasound. *Ultrasound Obstet Gynecol* 2015;46(1):125–6.
53. Tanaka Y, Mimura K, Kanagawa T, et al. Three-dimensional sonography in the differential diagnosis of interstitial, angular, and intrauterine pregnancies in a septate uterus. *J Ultrasound Med* 2014;33(11):2031–5.
54. Timor-Tritsch IE, Monteagudo A, Matera C, Veit CR. Sonographic evolution of cornual pregnancies treated without surgery. *Obstet Gynecol* 1992;79(6):1044–9.
55. Ackerman TE, Levi CS, Dashefsky SM, Holt SC, Lindsay DJ. Interstitial line: sonographic finding in interstitial (cornual) ectopic pregnancy. *Radiology* 1993;189(1):83–7.
56. Betran AP, Ye J, Moller AB, Souza JP, Zhang J. Trends and projections of caesarean section rates: global and regional estimates. *BMJ Glob Health* 2021;6(6):e005671.
57. Monteagudo A, Carreno C, Timor-Tritsch IE. Saline infusion sonohysterography in nonpregnant women with previous cesarean delivery: the “niche” in the scar. *J Ultrasound Med* 2001;20(10):1105–15.
58. Naji O, Abdallah Y, Bij De Vaate AJ, et al. Standardized approach for imaging and measuring Cesarean section scars using ultrasound. *Ultrasound Obstet Gynecol* 2012;39(3):252–9.
59. Miller R, Gyamfi-Bannerman C; Society for Maternal-Fetal Medicine (SMFM) Publications Committee. Electronic address: .pubs@smfm.org Society for Maternal-Fetal Medicine Consult Series #63: cesarean scar ectopic pregnancy. *Am J Obstet Gynecol* 2022;227(3):B9–20.
60. Vial Y, Petignat P, Hohlfield P. Pregnancy in a cesarean scar. *Ultrasound Obstet Gynecol* 2000;16(6):592–3.
61. Kaelin Agten A, Cali G, Monteagudo A, Oviedo J, Ramos J, Timor-Tritsch I. The clinical outcome of cesarean scar pregnancies implanted “on the scar” versus “in the niche”. *Am J Obstet Gynecol* 2017;216(5):510.e1–6.
62. Gonzalez N, Tulandi T. Cesarean scar pregnancy: a systematic review. *J Minim Invasive Gynecol* 2017;24(5):731–8.
63. Jordans IPM, Verberkt C, De Leeuw RA, et al. Definition and sonographic reporting system for cesarean scar pregnancy in early gestation: modified Delphi method. *Ultrasound Obstet Gynecol* 2022;59(4):437–49.
64. Jurkovic D, Hackett E, Campbell S. Diagnosis and treatment of early cervical pregnancy: a review and a report of two cases treated conservatively. *Ultrasound Obstet Gynecol* 1996;8(6):373–80.
65. Dibble EH, Lourenco AP. Imaging unusual pregnancy implantations: rare ectopic pregnancies and more. *AJR Am J Roentgenol* 2016;207(6):1380–92.
66. Condous G, Okaro E, Bourne T. The management of ectopic pregnancies and pregnancies of unknown location. *Gynecol Surg* 2004;1(2):81–6.
67. Barnhart KT. Early pregnancy failure: beware of the pitfalls of modern management. *Fertil Steril* 2012;98(5):1061–5.
68. Clement EG, Horvath S, McAllister A, Koelper NC, Sammel MD, Schreiber CA. The language of first-trimester nonviable pregnancy: patient-reported preferences and clarity. *Obstet Gynecol* 2019;133(1):149–54.
69. Rodgers SK, Chang C, DeBardeleben JT, Horrow MM. Normal and abnormal US findings in early first-trimester pregnancy: review of the Society of Radiologists in Ultrasound 2012 consensus panel recommendations. *RadioGraphics* 2015;35(7):2135–48.
70. Horrow MM. CHAPTER 31 - The First Trimester. In: Rumack CM, Levine D, eds. *Diagnostic Ultrasound, 2-Volume Set*. 6th ed. 1–16.
71. Yegul NT, Filly RA. The expanded amnion sign: evidence of early embryonic death. *J Ultrasound Med* 2009;28(10):1331–5.
72. Kamaya A, Krishnarao PM, Nayak N, Jeffrey RB, Maturen KE. Clinical and imaging predictors of management in retained products of conception. *Abdom Radiol (NY)* 2016;41(12):2429–34.
73. Creinin MD, Harwood B, Guido RS, Fox MC, Zhang J. NICHD Management of Early Pregnancy Failure Trial. Endometrial thickness after misoprostol use for early pregnancy failure. *Int J Gynaecol Obstet* 2004;86(1):22–6.
74. Reeves MF, Fox MC, Lohr PA, Creinin MD. Endometrial thickness following medical abortion is not predictive of subsequent surgical intervention. *Ultrasound Obstet Gynecol* 2009;34(1):104–9.
75. Zhang J, Gilles JM, Barnhart K, Creinin MD, Westhoff C, Frederick MM. National Institute of Child Health Human Development (NICHD) Management of Early Pregnancy Failure Trial. A comparison of medical management with misoprostol and surgical management for early pregnancy failure. *N Engl J Med* 2005;353(8):761–9.
76. Atri M, Rao A, Boylan C, Rasty G, Gerber D. Best predictors of grayscale ultrasound combined with color Doppler in the diagnosis of retained products of conception. *J Clin Ultrasound* 2011;39(3):122–7.
77. Kamaya A, Petrovitch I, Chen B, Frederick CE, Jeffrey RB. Retained products of conception: spectrum of color Doppler findings. *J Ultrasound Med* 2009;28(8):1031–41.
78. Grewal K, Al-Memar M, Fourie H, Stalder C, Timmerman D, Bourne T. Natural history of pregnancy-related enhanced myometrial vascularity following miscarriage. *Ultrasound Obstet Gynecol* 2020;55(5):676–82.
79. Timmerman D, Van den Bosch T, Peeraer K, et al. Vascular malformations in the uterus: ultrasonographic diagnosis and conservative management. *Eur J Obstet Gynecol Reprod Biol* 2000;92(1):171–8.
80. Groszmann YS, Healy Murphy AL, Benacerraf BR. Diagnosis and management of patients with enhanced myometrial vascularity associated with retained products of conception. *Ultrasound Obstet Gynecol* 2018;52(3):396–9.
81. Moradi B, Banihashemian M, Sadighi N, Shirali E, Saleem SA, Najafi E. Enhanced myometrial vascularity and AVM: a review on diagnosis and management. *J Clin Ultrasound* 2023;51(6):1051–8.
82. Petrovitch I, Beatty M, Jeffrey RB, Heerema-McKenney A. Subinvolution of the placental site. *J Ultrasound Med* 2009;28(8):1115–9.
83. Triantafyllidou O, Kastora S, Messina I, Kalampokis D. Subinvolution of the placental site as the cause of hysterectomy in young woman. *BMJ Case Rep* 2021;14(2):1–4.