


## NARRATIVE REVIEW



# Position paper on the physiology and nomenclature of dual circulation during venoarterial ECMO in adults

Jenelle Badulak<sup>1,2,3\*</sup> , Darryl Abrams<sup>4</sup>, Andrew M. Luks<sup>2</sup>, Bishoy Zakhary<sup>5</sup>, Steven A. Conrad<sup>6</sup>, Robert Bartlett<sup>7</sup>, Graeme MacLaren<sup>8</sup>, Leen Vercaemst<sup>9</sup>, Roberto Lorusso<sup>10</sup>, Lars Mikael Broman<sup>11,12</sup>, Cara Agerstrand<sup>4</sup>, Susanna Price<sup>13,14</sup>, Alain Combes<sup>15</sup>, Giles Peek<sup>16</sup>, Eddy Fan<sup>17</sup>, Kiran Shekar<sup>18</sup>, John Fraser<sup>18</sup> and Daniel Brodie<sup>19</sup> on behalf of the Extracorporeal Life Support Organization (ELSO)

© 2024 The Author(s)

### Abstract

When native blood flow through the aorta from the adult heart and lungs meets retrograde blood flow from an artificial heart and lung during venoarterial extracorporeal membrane oxygenation (VA-ECMO), the result is the creation of two separate circulations on either side of the blood flow mixing point. This phenomenon is known as dual circulation and is characterized by different content of oxygen and carbon dioxide between the circulations. There is currently a lack of clarity surrounding the nomenclature to describe this physiologic phenomenon in VA-ECMO and thus we endeavor to name and define these terms to facilitate clear communication and proper clinical management of these patients.

**Keywords:** Extracorporeal membrane oxygenation, Extracorporeal life support, Dual circulation, Differential oxygenation, Differential carbon dioxide, Mixing point

### Introduction

As the use of extracorporeal membrane oxygenation (ECMO) increases, it has become apparent that there is a lack of adequate terminology to describe dual (native and extracorporeal) circulations, which potentially occur during venoarterial (VA) ECMO support. Terminology describing this physiology has traditionally been imprecise and often inaccurate. Clarifying this terminology is important because it can affect interpretation of ECMO and patient data, impacting not only decisions about appropriate interventions, but also future research priorities. Additionally, while the concept of regional upper body hypoxemia has long been recognized, many

ECMO practitioners are not aware that carbon dioxide is also affected by dual circulation and that it is important to manage CO<sub>2</sub> content within the respective native and extracorporeal zones. In this narrative review, which extends the foundational work of the Maastricht Treaty position papers [1, 2], we describe the physiology, nomenclature, and implications for clinical management of dual circulation VA-ECMO. The nomenclature recommendations herein are endorsed by the Extracorporeal Life Support Organization (ELSO).

### Retrograde VA-ECMO blood flow and the establishment of dual circulation

Patients with severe cardiopulmonary failure may be supported using a range of mechanical circulatory support devices, including VA-ECMO. During VA-ECMO, blood is drained from a central vein, pumped through a membrane lung (ML) for gas exchange, and then returned

\*Correspondence: badulakj@uw.edu

<sup>1</sup> Department of Emergency Medicine, University of Washington, Seattle, WA, USA

Full author information is available at the end of the article

Jenelle Badulak and Darryl Abrams have contributed equally to this work.

under positive pressure to the arterial system. *Peripheral* VA-ECMO is the cannula configuration in which the return cannula is placed peripherally into a major artery outside the thoracic or abdominal cavity, e.g., femoral, subclavian, axillary, or carotid artery (electronic supplementary material, ESM 1). *Central* VA-ECMO, which requires a sternotomy or thoracotomy, is the cannula configuration in which the return cannula is placed into the intrathoracic aorta or brachiocephalic artery [1] (ESM 2).

Blood flow from the ECMO circuit can travel in an *anterograde* direction (in the natural direction of blood ejected from the heart) or *retrograde* direction (against the flow of blood ejected from the heart).

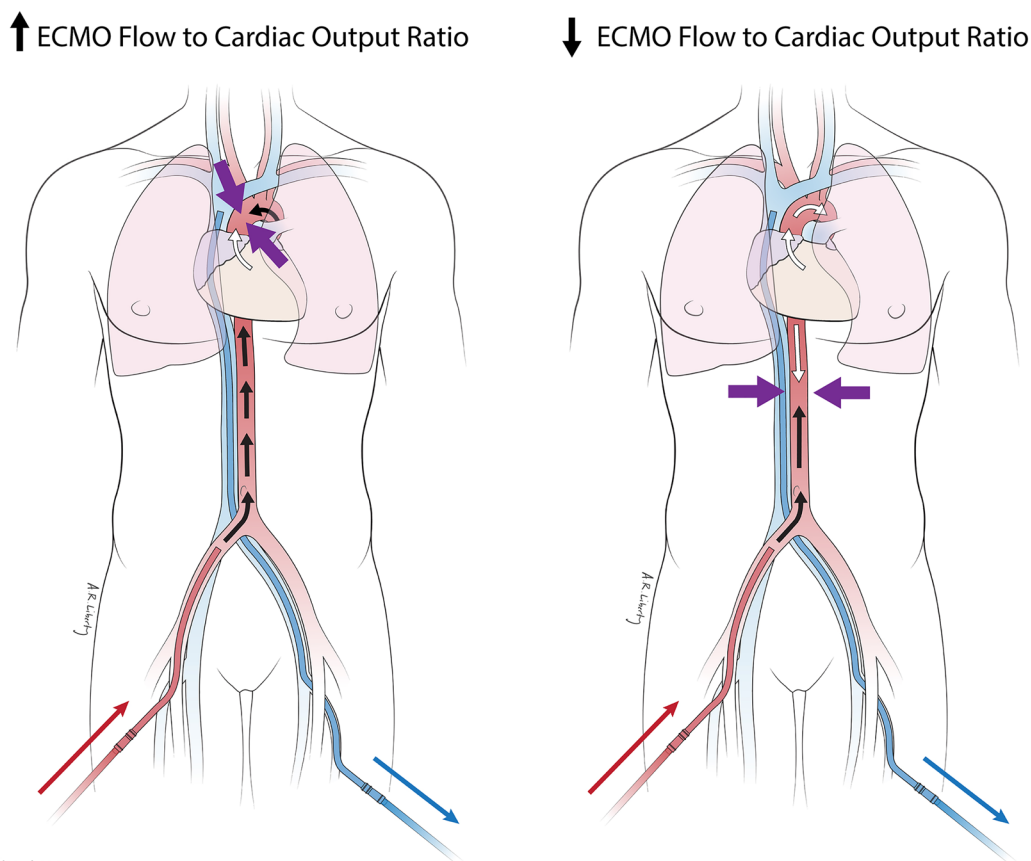
In peripheral VA-ECMO, most of the blood flow is directed retrograde through the cannulated artery and into the aorta against the flow of blood ejected from the left ventricle (LV) in an anterograde direction. These opposing flows are referred to as *competitive flows*. The location where competitive flows meet in the aorta is

### Take-home message

When native blood flow through the aorta from the adult heart and lungs meets retrograde blood flow from an artificial heart and lung (venoarterial extracorporeal membrane oxygenation), the result is the creation of two separate circulations on either side of the blood flow mixing point. This phenomenon is known as dual circulation and is characterized by different content of oxygen and carbon dioxide between the circulations.

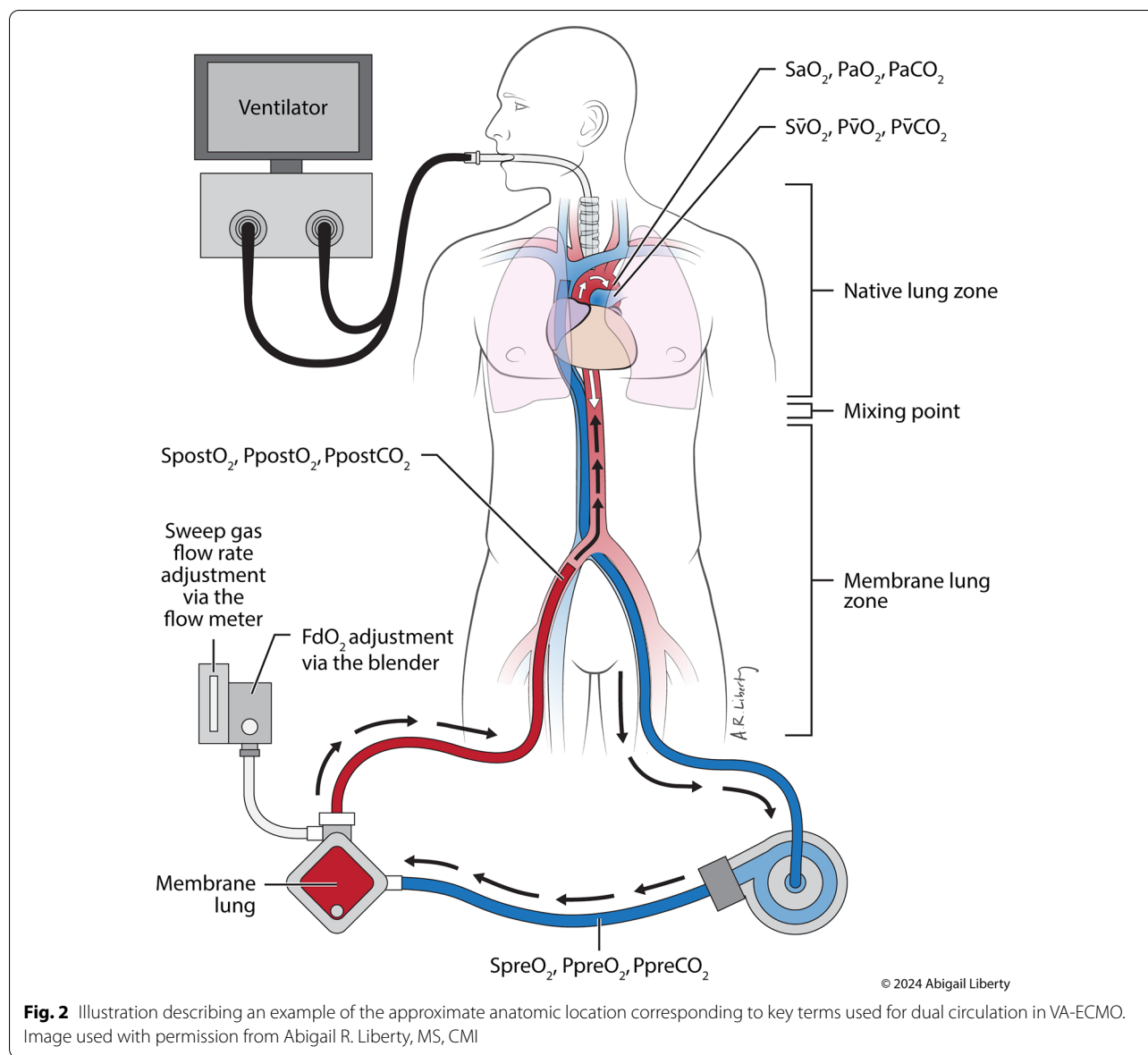
referred to as the *mixing point*, with the location of this point largely dependent on the magnitude of the pressure and blood flow generated by the ECMO pump relative to the pressure and blood flow out of the LV, as well as the precise position of the arterial return cannula (Fig. 1) [3]. While both the pressure and blood flow of the native heart and ECMO pump affect the mixing point, for the sake of simplicity we will use the term 'flow.'

In most types of central VA-ECMO, most of the blood flow is anterograde, with minimal retrograde flow limited



© 2017 CollectedMed, LLC

**Fig. 1** Competitive flows and mixing point in peripheral VA-ECMO. **a** Mixing point (arrows) located in the proximal aorta due to a high ratio of ECMO blood flow to cardiac output. **b** Mixing point (arrows) in the descending thoracic aorta due to a decreased ratio of ECMO blood flow to cardiac output. ECMO extracorporeal membrane oxygenation. Image used with permission from Columbia University Irving Medical Center



to the portion of the aorta between the return cannula and the aortic valve. The degree of retrograde flow depends on whether the LV is ejecting blood or not (the aortic valve is continuously closed). This proximal section of aorta feeds the coronary arteries, which may be clinically relevant if de-oxygenated blood from diseased lungs is being ejected by the LV.

In selected patients who need extracorporeal circulatory support despite preserved LV function, e.g., isolated right ventricular failure, blood may be reinfused into the pulmonary artery (PA), pulmonary vein (PV) or left atrium (LA). Under such circumstances, reinfused blood mixes with native blood flow from the pulmonary veins and is propelled entirely in an anterograde direction

because it is ejected by the LV, avoiding any competitive flow or mixing point within the aorta. While PA, PV, and LA reinfusion are not considered to be true VA-ECMO, as both sides of the heart are not partially bypassed, it is included here as a useful example to illustrate the contrast in physiology. The remainder of the discussion focuses on the physiology of competitive flows found in peripheral and, to a lesser degree, central VA-ECMO, when there is retrograde flow.

The content of oxygen and carbon dioxide in the blood on either side of the mixing point is predominantly determined by the native lung (NL) for native blood flow proximal to the mixing point, termed *NL zone*, and the ML for extracorporeal blood flow distal

to the mixing point, termed *ML zone* (Fig. 2). The phenomenon of two regions of the body (proximal and distal to the mixing point) being supplied by different sources of blood flow—and having different content of oxygen and carbon dioxide based on separate sources of gas exchange—is referred to as *dual circulation* [4]. Dual circulation is always present in VA-ECMO with the exception of the scenario when there is no native cardiac output and retrograde ECMO blood flow travels all the way to a persistently closed aortic valve.

### Key Terms

Term	Definition
Peripheral VA-ECMO	Cannula configuration in which the return cannula is placed peripherally into major arteries outside the thoracic or abdominal cavity, e.g., femoral, subclavian, axillary, or carotid artery
Central VA-ECMO	Cannula configuration in which the return cannula is placed inside the thoracic or abdominal cavity and for which cannulation of the cardiac structures, intrathoracic aorta, pulmonary vein or artery, or brachiocephalic artery requires a sternotomy or thoracotomy
Anterograde blood flow	The direction of blood flow ejected from the heart during normal physiology
Retrograde blood flow	The direction of blood flow infused by the VA-ECMO circuit which is opposite the normal direction of blood ejected from the heart
Competitive flows	The presence of anterograde flow generated by native cardiac output from the left ventricle and retrograde blood flow reinfused from the ECMO circuit
Mixing point	The location within the aorta where anterograde blood flow from the left ventricle meets retrograde reinfused blood flow from the ECMO circuit
Native lung (NL) zone	The region of blood flow starting at the aortic root and extending to the mixing point where oxygen and carbon dioxide content are determined by the native lung
Membrane lung (ML) zone	The region of blood flow starting at the arterial return cannula and extending to the mixing point where oxygen and carbon dioxide content are determined by the membrane lung
Dual circulation	The concept of two circulations in VA-ECMO when retrograde flow is present: 1) native heart and NL, 2) ECMO pump and ML

### Historical and recommended nomenclature of gas exchange in dual circulation

The presence of dual circulation due to retrograde flow during VA-ECMO may result in differences in the content of oxygen and carbon dioxide in different portions of the aorta and its corresponding arterial branches. Both circulations will have normal to high oxygen content if the NL and ML each exchange gas normally. However, when either NL or ML gas exchange is impaired, hypoxemia may develop in the respective zone. This phenomenon of differences in oxygen content between regions of the body has been referred to by a variety of terms, including “Harlequin syndrome”, “north-south syndrome”, “differential hypoxemia” and “mixing cloud” [4, 5]. However, these terms are imprecise, potentially confusing and, therefore, should be abandoned. The term Harlequin syndrome is already used to describe an entirely separate autonomic nervous system disorder and conveys no information about the precise physiological derangement. While north-south syndrome is perhaps more descriptive, it incorrectly implies an even split between the upper and lower portions of the body, whereas the mixing point may occur anywhere within the aorta, including proximal to the left subclavian artery. Differential hypoxemia suggests that hypoxemia is present on both sides of the mixing point and differs only in the degree of hypoxemia. While the blood in the proximal branches of the aorta may be hypoxemic due to NL gas exchange impairment (and potentially exacerbated by efforts to increase native cardiac output), the portion of the aorta supplied by the ML is typically *normoxemic* or *hyperoxemic*, except when there is malfunction of the ML. There is also need of a term that describes differing, even if slightly, normoxemic contents of oxygen in each zone. “Mixing cloud” is problematic due to conceptual confusion surrounding the foreign idea of a cloud of blood, which does not accurately describe the physiology. Importantly, none of these terms characterize differences in carbon dioxide content that can occur on either side of the mixing point. In addition, “decarboxylation” has been inaccurately used in the ECMO literature to describe CO<sub>2</sub> removal [6]. This term refers to the chemical reaction of removing a carboxyl group from a molecule. Likewise, ‘ventilation’ is a physiologic process restricted to the NL.

In lieu of these previously used terms, we propose differential content of oxygen to be termed *differential oxygenation*, and differential content of carbon dioxide, to be termed *differential carbon dioxide* to describe regional differences in oxygen and carbon dioxide content as created by dual circulation. Instead of decarboxylation, we recommend ‘CO<sub>2</sub> removal’ as the preferred term to describe the process by which the ML eliminates CO<sub>2</sub>.

from the blood. While the NL also removes  $\text{CO}_2$ , separation of these terms—using “ventilation” for the NL and “ $\text{CO}_2$  removal” for the ML—allows for clarity when speaking about analogous gas exchange processes in each gas-exchanging region. Furthermore, whereas  $\text{FiO}_2$  is used to describe the fraction of inspired oxygen in the NL,  $\text{FdO}_2$  should be used as the preferred term to represent the fraction of oxygen *delivered* to the ML—both because the oxygen from the ML is not “inspired” and because a single term used for two different gas sources may lead to medical error.  $\text{F}_s\text{O}_2$  is another term previously recommended, but not preferred, because it is already in current use for free sulfur dioxide [1].

### Key Terms

Term	Definition
Differential oxygenation	A situation in which the content of oxygen differs between the two sides of the mixing point
Differential carbon dioxide	A situation in which the content of carbon dioxide differs between the two sides of the mixing point
$\text{CO}_2$ removal	The process by which the membrane lung removes carbon dioxide ( $\text{CO}_2$ )
$\text{FdO}_2$	The fraction of oxygen delivered by the sweep gas into the membrane lung

### Dynamic nature of the mixing point in the setting of dual circulation

Because the mixing point location is determined by the relative magnitude of the competitive flows generated by the native heart and the ECMO circuit (Fig. 1), changes in blood flow from either pump affect the location of the mixing point within the aorta, and, in turn, the regions of the body supplied by each circulation. If LV blood flow is very low and retrograde ECMO blood flow is delivered through the femoral artery, the mixing point likely occurs in the proximal aorta with the majority of aortic—and, therefore, systemic—blood flow provided by the ECMO circuit (Fig. 1a). Assuming no change in ECMO blood flow, the mixing point moves more distally within the aorta as native blood flow from the LV increases (Fig. 1b). Multiple studies have visually demonstrated this mixing point with clinical imaging [3, 7–12] and computational fluid dynamics [13–15]. Importantly, the location of the mixing point, and thus the tissues perfused by the dual circulations of the NL and ML, is not static but changes over the course of an ECMO run.

Whereas femoral reinfusion involves retrograde flow originating in the iliac artery or distal aorta (ESM 1a),

reinfusion through the axillary, subclavian, or brachiocephalic arteries (ESM 1b) more commonly results in a more proximal mixing point within the aorta. Despite this difference, decreased LV blood flow still results in a mixing point closer to the aortic valve, while increased LV blood flow shifts the mixing point closer to the return cannula.

There will be no mixing point within the aorta in the presence of very poor or no cardiac contractility, or/and in association with very high ECMO-generated flow, which leads to a continuously closed aortic valve. This is a well-known complication of VA-ECMO with a consequent lack of pulsatile flow visible on the systemic arterial pressure curve, persistent aortic valve closure, LV and atrial distension, blood stasis on echocardiography, retrograde diastolic transmitral flow, retrograde pulmonary venous flow, as well as increased pulmonary capillary pressure and pulmonary edema, and eventual cardiopulmonary clot [16, 17]. This pathologic state of LV non-ejection, and absence of dual circulations, must be corrected (see below, clinical implications for management), and thus it follows that the *desired* physiologic condition is the presence of dual circulation.

In the presence of dual circulation, it is important to establish the approximate location of the mixing point to determine which regions of the body are supplied by which circulation, whether each region has appropriate oxygen and carbon dioxide content, and the interplay between the function of the native heart and ECMO pump. While this cannot be readily measured at present, an estimate based on native heart pulsatility may be made. For example, if the right upper extremity (RUE) systemic arterial pulse pressure is  $>20$  mmHg in a patient with femoral VA-ECMO, the mixing point is often distal to the brachiocephalic artery. Of note, use of a mechanical LV vent, such as a microaxial flow device or intra-aortic balloon pump, affects the location of the mixing point, by moving it further down the aorta, independently of the native ventricular ejection volume.

To ascertain a more precise location of the mixing point, additional information can be gleaned by measuring oxygen content in various locations. This is best done by decreasing either the  $\text{FiO}_2$  or  $\text{FdO}_2$  while setting the other to 1.0 and then comparing the partial pressure of arterial oxygen ( $\text{PaO}_2$ ) of the RUE and post-membrane partial pressure of oxygen ( $\text{P}_{\text{postO}_2}$ ) (Fig. 2). For example, if the RUE  $\text{PaO}_2$  is consistent with an expected functioning NL value at an  $\text{FiO}_2$  of 0.40 and the  $\text{P}_{\text{postO}_2}$  is hyperoxemic, consistent with a functioning ML with  $\text{FdO}_2$  of 1.0, then the mixing point is very likely distal to the brachiocephalic artery. If the patient also happens to have an arterial line in the left upper extremity (LUE), and if the  $\text{PaO}_2$  measured in the LUE (representative of the left subclavian artery) also reflects NL gas exchange, then the



mixing point is distal to the left subclavian artery. Cerebral vasculature must likewise be receiving blood flow from the NL. However, if LUE PaO<sub>2</sub> reflects ML gas exchange (with the RUE PaO<sub>2</sub> reflecting the NL), then the mixing point is somewhere proximal to the left subclavian artery, with uncertainty as to whether the carotid arteries receive blood from the native or extracorporeal circulations. If the RUE PaO<sub>2</sub> reflects ML gas exchange, the mixing point is proximal to the brachiocephalic artery, implying that the other great vessels—and by extension the cerebral vasculature—are receiving blood from the ML circulation. Importantly, coronary oxygenation, whether supplied by the ML or NL cannot be determined in this case. When making adjustments to the sweep gas flow rate and FdO<sub>2</sub>, the sweep gas should never be shut off in VA-ECMO because it will result in a right to left hypoxemic shunt (as opposed to veno-venous [VV] ECMO, where it is common practice for weaning).

Using arterial oxygen saturation estimated by pulse oximetry (SpO<sub>2</sub>) on various parts of the body to identify the mixing point will only work if the ML and NL are emitting blood with significantly differing oxygen saturations, i.e., when either the ML or NL is dysfunctional thus emitting hypoxemic blood. When both lungs are functional, it is more practical to identify the location of the mixing point using PaO<sub>2</sub>. Notably, any intervention to manage abnormalities in oxygen (or carbon dioxide) content should be performed within either the NL or ML zone based on blood gases, or arterial oxygen saturation, reflective of that zone. It must also be emphasized that these zones are dynamic, changing with any change in native cardiac output or/and ECMO blood flow during the duration of ECMO support. Importantly, the RUE is the first measurable location on the body of the NL zone SpO<sub>2</sub>, thus it must be continuously monitored to quickly alert the clinician of hypoxemic blood being ejected from the heart, and subsequently into the cerebral circulation. Some centers have also employed near infrared spectroscopy (NIRS) monitoring on the patient's head to aid in early detection of cerebral hypoxia [18].

## Differential oxygenation

The oxygen content of blood in the extracorporeal circuit as it exits the ML—reflected by the P<sub>post</sub>O<sub>2</sub> and oxygen saturation (S<sub>post</sub>O<sub>2</sub>)—is determined by the ML gas exchange (and thereby FdO<sub>2</sub>), ECMO blood flow rate, and pre-membrane oxygen saturation (S<sub>pre</sub>O<sub>2</sub>). The oxygen content of blood in the native circulation as it exits the NL—reflected by the PaO<sub>2</sub>, arterial oxygen saturation (SaO<sub>2</sub>) and SpO<sub>2</sub>—is determined by NL gas exchange (and thereby FiO<sub>2</sub> and other ventilator settings, if intubated), pulmonary blood flow, and mixed venous oxygen saturation (S<sub>v</sub>O<sub>2</sub>) (Fig. 2). Hemoglobin concentration affects oxygen content in both circulations. Local oxygen consumption ( $\dot{V}O_2$ ) may vary between the ML and NL zones based on the metabolic activity of the organs in those zones. This will be reflected in the S<sub>v</sub>O<sub>2</sub> and S<sub>pre</sub>O<sub>2</sub>, depending on where the drainage cannula is located in the body. Of note, dual circulations during VA-ECMO can influence the ratio and oxygen content of superior and inferior caval blood returning to the heart, making oxygen content higher or lower in the PA than it would be in the normal physiologic state without ECMO. Here, we use the term S<sub>v</sub>O<sub>2</sub> to denote the anatomic blood sampling location in the pulmonary artery (not to refer to the true blend of all the body's vascular beds' venous streams returning to the heart).

While the term *differential oxygenation* denotes the fact that the oxygen content differs between each zone, it is important to further clarify the term to facilitate description of pathologic scenarios where oxygen content in the blood is low (hypoxemia) and where oxygen delivery is insufficient for tissue demand (hypoxia). Thus, there are three potential scenarios (Table 1): (1) differential oxygenation with neither hypoxemia nor tissue hypoxia, (2) differential oxygenation with regional hypoxemia but no tissue hypoxia, and (3) differential oxygenation with regional hypoxemia and tissue hypoxia (as depicted by an increase in lactate or other evidence of end-organ

**Table 1 Descriptions of the various scenarios for differential oxygenation during VA-ECMO when the mixing point is distal to the brachiocephalic artery**

Scenario	Native lung gas exchange	Example RUE SaO <sub>2</sub>	Example RUE PaO <sub>2</sub> (mmHg)	Membrane lung gas exchange	Example S <sub>post</sub> O <sub>2</sub>	Example P <sub>post</sub> O <sub>2</sub> (mmHg)	Lactate
1	Preserved	≥ 88%	95	Preserved	≥ 88%	400	Normal
2							
A	Impaired	< 88%	50	Preserved	≥ 88%	400	Normal
B	Preserved	≥ 88%	95	Impaired	< 88%	50	Normal
3							
A	Impaired	< 88%	50	Preserved	≥ 88%	400	Elevated
B	Preserved	≥ 88%	95	Impaired	< 88%	50	Elevated

RUE right upper extremity

hypoxia). Scenario 1 occurs when oxygen content differs between NL and ML zones but the  $\text{SaO}_2$  is nonetheless in a range in both circulations that is determined by the bedside clinicians to be clinically appropriate. Of note, potentially harmful non-physiologic hyperoxemia (extremely high  $\text{PO}_2$ ) may occur in either zone. Scenario 2 occurs when there is sufficiently severe dysfunction of either the NL (2A) or ML (2B) such that hypoxemia occurs, but oxygen delivery is sufficient to avoid tissue hypoxia. Interventions to correct hypoxemia in this scenario may be unnecessary. Scenario 3 occurs when there is sufficiently severe dysfunction of either the NL (3A) or the ML (3B), leading not only to hypoxemia, but also to tissue hypoxia. Attempts to correct hypoxemia resulting in tissue hypoxia are almost always appropriate.

### Key Terms

Term	Definition
Differential oxygenation	A situation in which the content of oxygen differs between the two sides of the mixing point
Without hypoxemia	When $\text{PO}_2$ differs between the NL and ML zones but there is no hypoxemia
With regional hypoxemia without hypoxia	When the ML or NL zone is hypoxic but no tissue hypoxia is seen
With regional hypoxemia and hypoxia	When the ML or NL zone is hypoxic and tissue hypoxia is present

ML membrane lung, NL native lung

### Differential carbon dioxide

Similar to regional differences in oxygenation, ventilation by the NL and  $\text{CO}_2$  removal by the ML may differ

between the two circulations.  $\text{CO}_2$  in the ML zone—reflected by the post-membrane partial pressure of carbon dioxide ( $\text{P}_{\text{post}}\text{CO}_2$ )—is determined by the ML sweep gas flow rate, ML dead space fraction, diffusion properties of the ML, pre-membrane partial pressure of carbon dioxide ( $\text{P}_{\text{pre}}\text{CO}_2$ ), and ECMO blood flow (particularly at lower blood flows).  $\text{CO}_2$  in the NL zone—reflected by the partial pressure of arterial carbon dioxide ( $\text{PaCO}_2$ )—is determined by NL alveolar ventilation, diffusion properties of the NL, mixed venous  $\text{CO}_2$  content, and pulmonary blood flow (Fig. 2). The  $\text{CO}_2$  content in both circulations is further determined by hemoglobin concentration, and oxygen saturation (Haldane effect). Carbon dioxide production ( $\dot{V}\text{CO}_2$ ) will impact the amount of  $\text{CO}_2$  delivered to both the ML and the NL.

As with differential oxygenation, it is important to define scenarios where differential carbon dioxide is pathologic and results in acid-base derangements. There are three potential scenarios (Table 2): (1) differential carbon dioxide with normocapnia, (2) differential carbon dioxide with regional hypercapnia, (3) differential carbon dioxide with regional hypocapnia. Whether interventions are warranted to correct or normalize pH or  $\text{PCO}_2$  depends on the individual patient's physiology and ability to tolerate derangements in pH and  $\text{PCO}_2$ . Of note, avoiding derangements is particularly important in pregnant patients and patients with neurologic emergencies. Additionally, exacerbation of differential carbon dioxide can occur if hyper/hypocapnia in the NL and ML zones, or changes in tissue metabolism, go unnoticed or are improperly managed.

**Table 2 Descriptions of the various scenarios for regional  $\text{PCO}_2$  differences during VA-ECMO when the mixing point is distal to the brachiocephalic artery**

Scenario	Native lung status	RUE $\text{PaCO}_2$ (mmHg)	Membrane lung status	$\text{P}_{\text{post}}\text{CO}_2$ (mmHg)	Comment
1	Normal	35 – 45	Normal	35 – 45	While both $\text{CO}_2$ tensions may be normal, the numerical value may still differ between circulations
2					
A	Hypoventilation	> 45	Normal	35 – 45	NL hypercapnia
B	Normal	35 – 45	Decreased $\text{CO}_2$ removal	> 45	ML hypercapnia
3					
A	Hyperventilation	< 35	Normal	35 – 45	NL hypocapnia
B	Normal	35 – 45	Increased $\text{CO}_2$ removal	< 35	ML hypocapnia

RUE right upper extremity

## Key Terms

Term	Definition
Differential carbon dioxide	A situation in which the content of carbon dioxide differs between the two sides of the mixing point
With normocapnia	When $PCO_2$ is marginally different in the NL and ML zones without hypocapnia or hypercapnia
With regional hypocapnia	When there is hypocapnia in the ML or NL zone
With regional hypercapnia	When there is hypercapnia in the ML or NL zone

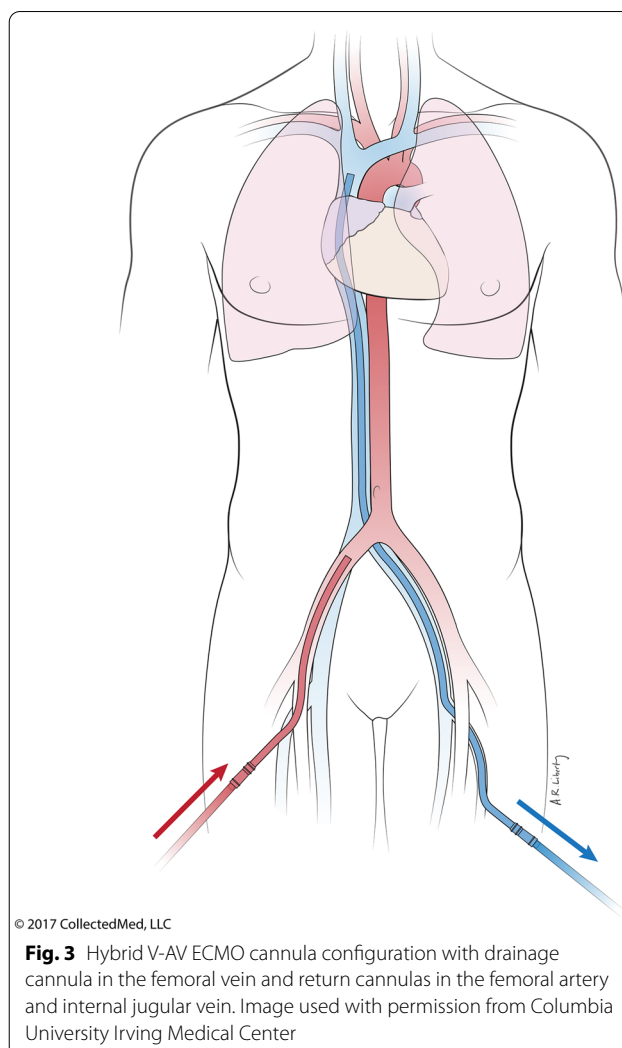
ML membrane lung, NL native lung

## Implications for clinical management

The region from which a blood gas measurement is sampled, (i.e., in the distribution of the NL or ML zone) dictates which lung (native or membrane) should be manipulated when attempting to manage gas exchange. To do this, a general understanding of where the mixing point resides during retrograde flow VA-ECMO is needed—bearing in mind that the mixing point may be dynamic, even over short periods of time. Most of the time, achieving some degree of LV ejection, whether via afterload reduction (weaning vasoconstrictors or starting vasodilators, using positive pressure ventilation, hemodynamically tolerated ECMO blood flow reduction), or inotropes, or mechanical LV vent (microaxial flow device, intra-aortic balloon pump), is required to mitigate LV distention [16, 17]. When sufficient LV ejection is achieved, the mixing point is most often distal to the brachiocephalic artery. Therefore, in general, support provided to the NL (usually the ventilator) should be adjusted based on RUE blood gases, and the ML (sweep gas) adjusted based on post-membrane blood gases.

## Hypoxemia

One of several interventions may be indicated to correct regional hypoxemia with/without tissue hypoxia depending on the affected zone. Within the NL zone (Table 1, scenario 2A and 3A), interventions may include ensuring the drainage cannula is draining the superior vena cava, adjusting mechanical ventilation settings, and/or conversion to veno-arterio-venous (V-AV)-ECMO (Fig. 3). To allow cross-circulation of the dual circulations, ideally a femoral drainage cannula is always placed with the tip in the superior vena cava, alternatively the drainage cannula can be placed in the internal jugular vein [19–23]. Mechanical ventilator settings should be augmented early to mitigate alveolar filling and pulmonary shunt physiology, which will commonly be required in the patient with cardiogenic pulmonary edema. Increasing the flow through a microaxial LV vent, if one is in place, can also



be employed to decongest the LV and alleviate pulmonary edema. If the patient has concomitant acute respiratory distress syndrome (ARDS), the best strategy to avoid ventilator-induced lung injury (VILI) may be early conversion to the V-AV hybrid cannula configuration with the addition of a venous return limb. A common scenario is a patient in cardiogenic shock with concomitant ARDS initially placed on VA-ECMO. When the heart recovers before the lungs, the mixing point moves distally in the aorta leading to upper body hypoxemia. Initially, maneuvers to optimize the ventilator for ARDS management can be undertaken and, if unsuccessful, the circuit is usually converted to V-AV [24]. Alternatively, the mixing point can be moved more proximal to the ascending aorta to reduce the likelihood of hypoxemic NL circulation supplying the cerebral circulation and avoid cerebral hypoxia, but it is important to note that this may not correct coronary hypoxia. Moving the mixing point more proximally can be achieved by relocating the arterial



return cannula to the upper body, e.g., the right axillary, right subclavian, or brachiocephalic artery [25, 26], or conversion to central cannulation with the return cannula in the proximal aorta. Another option, albeit rarely employed, is to use a long instead of short femoral arterial return cannula [27, 28]. Increasing ECMO blood flow or decreasing the flow of a microaxial LV vent [5] would move the mixing point more proximal. However, these maneuvers worsen the underlying problem by increasing LV afterload leading to decreased LV ejection, worsened pulmonary edema, blood stasis and eventual cardiopulmonary clot. Thus these maneuvers could be temporarily employed to manage circumstances of severe cerebral hypoxemia, but the more durable aforementioned alternative strategies that don't perpetuate the problem of LV congestion are preferred and should be pursued as soon as possible. Within the ML zone (Table 1, scenario 2B and 3B), interventions may include adjusting the  $FdO_2$  or replacing the ML, as appropriate [29].

### Hyper/hypocapnia

In the setting of regional hyper/hypocapnia, one of several interventions may be indicated to correct the derangement, depending on the affected zone. Within the NL zone (Table 2, scenario 2A and 3A), ventilation of the NL may be adjusted if the patient is mechanically ventilated. It is more difficult to adjust NL ventilation in the spontaneously breathing patient aside from avoiding central nervous system depressants that cause hypoventilation. While one could utilize cannulation reconfiguration, as previously mentioned in the section on oxygenation [19–28], to reduce the likelihood of NL circulation supplying the cerebral circulation and to improve the ability to regulate cerebral hyper/hypocapnia, this is rarely performed. Within the ML zone (Table 2, scenario 2B and 3B), interventions include adjusting  $CO_2$  removal using the sweep gas flow rate or replacing the ML, as appropriate [29].

Importantly, because gas content in each circulation exists independently, adjustments in either NL ventilation or ML  $CO_2$  removal should be performed to address hyper- or hypocapnia in the respective zone, as such changes will have minimal, if any, impact on  $CO_2$  content in the other circulation. This is a key point that often confounds clinicians at the bedside, because historically attention has been focused on management of differential oxygenation while differential carbon dioxide content was not recognized until more recently. Further, if changes are made using the wrong blood gas data, e.g., titrating the sweep gas flow rate to the RUE  $PaCO_2$ , exacerbation of differential carbon dioxide leading to regional hyper/hypocapnia can occur. For example, when the kidneys are perfused by the ML circulation (whenever the mixing

point is proximal to the origin of the renal arteries) and exposed to hypercapnia and acidemia despite normal NL ventilation (Table 2, scenario 2B), the response is an increase in renal acid excretion, leading to systemic metabolic alkalosis, including within the NL zone. Management of this scenario requires increasing the sweep gas flow rate within the ML to create an alkalemic environment for the kidneys that would prompt bicarbonate excretion. Similarly, in patients presenting with NL hypoventilation (Table 2, scenario 2A), efforts to correct hypercapnia by increasing the sweep gas flow rate result in exposure by the kidneys to an extracorporeal-induced respiratory alkalosis that triggers increased bicarbonate excretion and loss of systemic bicarbonate buffering for the NL hypercapnia, potentially resulting in a dangerous level of acidemia within the NL zone.

### Summary

Standardizing terminology is important for accurately describing changes in oxygen and carbon dioxide content that may occur during dual circulation VA-ECMO. Understanding and accurately describing the physiological impact of VA-ECMO when blood is infused opposite (retrograde) the direction of blood flow ejected from the heart—with such terms as *competitive flow*, *dual circulation*, *membrane* and *native lung zones*, *mixing point*, *differential oxygenation* and *differential carbon dioxide*—is crucial for the optimal management of these complex patients. Importantly, akin to oxygenation, carbon dioxide is affected by dual circulation, and it is important to manage  $CO_2$  content within the respective native and extracorporeal zones.

### Supplementary Information

The online version contains supplementary material available at <https://doi.org/10.1007/s00134-024-07645-8>.

### Abbreviations

$CO_2$ : Carbon dioxide; ECMO: Extracorporeal membrane oxygenation;  $FdO_2$ : Fraction of oxygen delivered to the membrane lung;  $FiO_2$ : Fraction of inspired oxygen; LA: Left atrium; LUE: Left upper extremity; LV: Left ventricle; ML: Membrane lung; NL: Native lung;  $O_2$ : Oxygen; PA: Pulmonary artery;  $P_aCO_2$ : Partial pressure of arterial carbon dioxide;  $P_aO_2$ : Partial pressure of arterial oxygen;  $PO_2$ : Partial pressure of oxygen (unspecified location, e.g., arterial, venous, pre/post membrane, etc.);  $P_{post}CO_2$ : Post-membrane partial pressure of carbon dioxide;  $P_{post}O_2$ : Post-membrane partial pressure of oxygen;  $P_{pre}CO_2$ : Pre-membrane partial pressure of carbon dioxide;  $P_{pre}O_2$ : Pre-membrane partial pressure of oxygen; PV: Pulmonary vein; RUE: Right upper extremity;  $S_aO_2$ : Arterial oxygen saturation;  $S_pO_2$ : Arterial oxygen saturation estimated by pulse oximetry;  $S_{post}O_2$ : Post-membrane oxygen saturation;  $S_{pre}O_2$ : Pre-membrane oxygen saturation;  $S_vO_2$ : Mixed venous oxygen saturation; VA: Venoarterial;  $\dot{V}CO_2$ : Carbon dioxide production;  $\dot{V}O_2$ : Oxygen consumption.

### Author details

<sup>1</sup> Department of Emergency Medicine, University of Washington, Seattle, WA, USA. <sup>2</sup> Division of Pulmonary, Critical Care and Sleep Medicine, University of Washington, Seattle, WA, USA. <sup>3</sup> Division of Cardiothoracic Surgery,

University of Washington, Seattle, WA, USA. <sup>4</sup> Division of Pulmonary, Allergy, and Critical Care Medicine, Columbia University College of Physicians and Surgeons, New York, NY, USA. <sup>5</sup> Division of Pulmonary and Critical Care Medicine, Oregon Health and Science University, Portland, OR, USA. <sup>6</sup> Departments of Medicine, Emergency Medicine, Pediatrics and Surgery, Louisiana State University Health Sciences Center Shreveport, Shreveport, LA, USA. <sup>7</sup> Department of Surgery, University of Michigan, Ann Arbor, MI, USA. <sup>8</sup> Cardiothoracic ICU, National University Hospital, Singapore, Singapore. <sup>9</sup> University Hospital Gasthuisberg, Louvain, Belgium. <sup>10</sup> Cardiothoracic Surgery Department, Heart and Vascular Center, Maastricht University Medical Center, Maastricht, Netherlands. <sup>11</sup> ECMO Centre Karolinska, Karolinska University Hospital, Stockholm, Sweden. <sup>12</sup> Department of Physiology and Pharmacology, Karolinska Institutet, Stockholm, Sweden. <sup>13</sup> Royal Brompton Hospital, London, UK. <sup>14</sup> National Heart and Lung Institute, Imperial College, London, UK. <sup>15</sup> Department of Intensive Care Medicine, Sorbonne University, La Pitié-Salpêtrière Hospital, Paris, France. <sup>16</sup> Division of Cardiothoracic Surgery, University of Florida Shands Children's Hospital, Congenital Heart Center at University of Florida Health, Gainesville, FL, USA. <sup>17</sup> Interdepartmental Division of Critical Care Medicine, University of Toronto, Toronto, Canada. <sup>18</sup> Critical Care Research Group, The Prince Charles Hospital, University of Queensland, Brisbane, QLD, Australia. <sup>19</sup> Department of Medicine, Johns Hopkins University School of Medicine, Baltimore, MD, USA.

### Acknowledgements

The authors would like to thank Thomas Mueller for his expert revisions to the manuscript.

### Author contributions

JB: concept and design, literature search, drafted article. DA: literature search, drafted article. AL: concept and design, critical revision. BZ: concept and design, literature search, critical revision. SC: concept and design, critical revision. RB: concept and design, critical revision. GMacL: concept and design, literature search, critical revision. Leen Vercaemst: critical revision. RL: critical revision. LMB: critical revision. CA: concept and design, critical revision. SP: critical revision. AC: critical revision. GP: critical revision. EF: critical revision. KS: critical revision. JF: critical revision. DB: concept and design, literature search, critical revision. All authors approved the final version of the article submitted for publication.

### Data availability

Not applicable.

### Declarations

### Conflicts of interest

JB is the immediate past chair of the Extracorporeal Life Support Organization (ELSO) Nominations and Membership Committee and a member of the ELSO Education Committee. DB received research support from and consults for LivaNova. He has been on the medical advisory boards for Xenios, Medtronic, Inspira and Cellenkos. He is the President-elect of the ELSO and the Chair of the Executive Committee of the International ECMO Network (ECMONet), and he writes for UpToDate. RB serves on the ELSO Board of Directors. AC receives research funding and personal fees from Getinge, Baxter, and Xenios. RL is a consultant for Medtronic, LivaNova, Xenios and Eurosets, receives personal fees from Abiomed, received research grants from Medtronic and LivaNova, and he is the chair of the ELSO Research Committee. KS receives research support from Queensland Health and is a member of the Scientific Committee of ECMONet, and Education and Guidelines committees of ELSO. GMacL is the president of ELSO. BZ is the immediate past chair of the ELSO Education Committee. CA writes for UpToDate, and is the immediate past chair of the ELSO Conference Committee. EF reports personal fees from ALung Technologies, Baxter, Getinge, Inspire, Vasomune, and Zoll Medical outside the submitted work, and is the immediate past chair of the ELSO Research Committee. JF has received grants from Xenios, Mera, Fischer and Paykel, and he is co-founder BiVACOR total artificial hearts. LMB is a consultant for Xenios/Fresenius, Eurosets, and HemoCue, and member of EuroELSO Scientific Committee. The remaining authors declare no conflicts of interest and have no financial disclosures. There was no financial support for this study.

### Open Access

This article is licensed under a Creative Commons Attribution-NonCommercial 4.0 International License, which permits any non-commercial use, sharing, adaptation, distribution and reproduction in any medium or format, as long as you give appropriate credit to the original author(s) and the source, provide a link to the Creative Commons licence, and indicate if changes were made. The images or other third party material in this article are included in the article's Creative Commons licence, unless indicated otherwise in a credit line to the material. If material is not included in the article's Creative Commons licence and your intended use is not permitted by statutory regulation or exceeds the permitted use, you will need to obtain permission directly from the copyright holder. To view a copy of this licence, visit <http://creativecommons.org/licenses/by-nc/4.0/>.

### Publisher's Note

Springer Nature remains neutral with regard to jurisdictional claims in published maps and institutional affiliations.

Received: 1 May 2024 Accepted: 2 September 2024

Published: 18 November 2024

### References

1. Broman LM, Taccone FS, Lorusso R, Malfertheiner MV, Pappalardo F, Di Nardo M, Belliato M, Bembea MM, Barbaro RP, Diaz R, Grazioli L, Pellegrino V, Mendonca MH, Brodie D, Fan E, Bartlett RH, McMullan MM, Conrad SA (2019) The ELSO Maastricht Treaty for ECLS nomenclature: abbreviations for cannulation configuration in extracorporeal life support—a position paper of the Extracorporeal Life Support Organization. *Crit Care* 23(1):36. <https://doi.org/10.1186/s13054-019-2334-8>. PMID:30736845;PMCID:PMC6367794
2. Conrad SA, Broman LM, Taccone FS, Lorusso R, Malfertheiner MV, Pappalardo F, Di Nardo M, Belliato M, Grazioli L, Barbaro RP, McMullan DM, Pellegrino V, Brodie D, Bembea MM, Fan E, Mendonca M, Diaz R, Bartlett RH (2018) The extracorporeal life support organization Maastricht treaty for nomenclature in extracorporeal life support. A position paper of the extracorporeal life support organization. *Am J Respir Crit Care Med* 198(4):447–451. <https://doi.org/10.1164/rccm.201710-2130CP>
3. Napp LC, Brehm M, Kühn C, Schäfer A, Bauersachs J (2015) Heart against veno-arterial ECMO: competition visualized. *Int J Cardiol* 187:164–165. <https://doi.org/10.1016/j.ijcard.2015.03.311>
4. Falk L, Sallissalmi M, Lindholm JA, Lindfors M, Frenckner B, Broomé M, Broman LM (2019) Differential hypoxemia during venoarterial extracorporeal membrane oxygenation. *Perfusion* 34(1\_suppl):22–29. <https://doi.org/10.1177/0267659119830513>
5. Giunta M, Recchia EG, Capuano P, Toscano A, Attisani M, Rinaldi M, Brazzi L (2023) Management of harlequin syndrome under ECPella support: a report of two cases and a proposed approach. *Ann Card Anaesth* 26(1):97–101. [https://doi.org/10.4103/aca.aca\\_176\\_21](https://doi.org/10.4103/aca.aca_176_21)
6. Laskey D, Housman B, Dawodu G, Scheinin S (2023) Intraoperative extracorporeal support during lung transplantation: not just for the high-risk patient. *J Clin Med* 13(1):192. <https://doi.org/10.3390/jcm13010192>
7. Buchtele N, Staudinger T, Schwameis M, Schörgenhofer C, Herkner H, Hermann A, UltraECMO investigators (2020) Feasibility and safety of watershed detection by contrast-enhanced ultrasound in patients receiving peripheral venoarterial extracorporeal membrane oxygenation: a prospective observational study. *Crit Care* 24(1):126. <https://doi.org/10.1186/s13054-020-02849-y>
8. Angleitner P, Röggl M, Laufer G, Wiedemann D (2016) Watershed of veno-arterial extracorporeal life support. *Eur J Cardiothorac Surg* 50(4):785. <https://doi.org/10.1093/ejcts/ezw185>
9. Hoepfer MM, Tudorache I, Kühn C, Marsch G, Hartung D, Wiesner O, Boenisch O, Haverich A, Hinrichs J (2014) Extracorporeal membrane oxygenation watershed. *Circulation* 130(10):864–865. <https://doi.org/10.1161/CIRCULATIONAHA.114.011677>
10. Lambert L, Grus T, Balik M, Fichtl J, Kavan J, Belohlavek J (2017) Hemodynamic changes in patients with extracorporeal membrane oxygenation

- (ECMO) demonstrated by contrast-enhanced CT examinations—implications for image acquisition technique. *Perfusion* 32(3):220–225. <https://doi.org/10.1177/0267659116677308>
11. Napp LC, Schmitt JD, Tongers J, Schäfer A (2018) The short- and long-term risks of venoarterial extracorporeal membrane oxygenation watershed. *Eur J Cardiothorac Surg* 53(4):894. <https://doi.org/10.1093/ejcts/ezx375>
  12. L'Hoyes W, Rosseel T, Jacobs B, Van Edom C, Tavazzi G, Voigt JU, Price S, Dauwe DF, Vandenbriele C (2024) Blood speckle imaging in critical care: a new tool in mechanical circulatory support management. *Circ Heart Fail*. <https://doi.org/10.1161/CIRCHEARTFAILURE.123.010697>
  13. Stevens MC, Callaghan FM, Forrest P, Bannon PG, Grieve SM (2017) Flow mixing during peripheral veno-arterial extra corporeal membrane oxygenation—a simulation study. *J Biomech* 11(55):64–70. <https://doi.org/10.1016/j.jbiomech.2017.02.009>
  14. Stevens MC, Callaghan FM, Forrest P, Bannon PG, Grieve SM (2018) A computational framework for adjusting flow during peripheral extracorporeal membrane oxygenation to reduce differential hypoxia. *J Biomech* 5(79):39–44. <https://doi.org/10.1016/j.jbiomech.2018.07.037>
  15. Zhang Q, Gao B, Chang Y (2018) The numerical study on the effects of cardiac function on the aortic oxygen distribution. *Med Biol Eng Comput* 56(7):1305–1313. <https://doi.org/10.1007/s11517-017-1777-9>
  16. Dickstein ML (2018) The startling relationship and Veno-Arterial ECMO: ventricular distension explained. *ASAIO J* 64(4):497–501. <https://doi.org/10.1097/MAT.0000000000000660>
  17. Soleimani B, Pae WE (2012) Management of left ventricular distension during peripheral extracorporeal membrane oxygenation for cardiogenic shock. *Perfusion* 27(4):326–331. <https://doi.org/10.1177/0267659112443722>
  18. Yu Y, Fang X, Xu Z, Li T, Yan J (2024) To identify Harlequin syndrome in patients with venoarterial extracorporeal membrane oxygenation using radial near-infrared spectroscopy. *Crit Care* 28(1):16. <https://doi.org/10.1186/s13054-023-04793-z>
  19. Hou X, Yang X, Du Z, Xing J, Li H, Jiang C, Wang J, Xing Z, Li S, Li X, Yang F, Wang H, Zeng H (2015) Superior vena cava drainage improves upper body oxygenation during veno-arterial extracorporeal membrane oxygenation in sheep. *Crit Care* 19(1):68. <https://doi.org/10.1186/s13054-015-0791-2>
  20. Kitamura M, Shibuya M, Kurihara H, Akimoto T, Endo M, Koyanagi H (1997) Effective cross-circulation technique of venoarterial bypass for differential hypoxia condition. *Artif Organs* 21(7):786–788. <https://doi.org/10.1111/j.1525-1594.1997.tb03743.x>
  21. Lindfors M, Frenckner B, Sartipy U, Bjällmark A, Broomé M (2017) Venous cannula positioning in arterial deoxygenation during Veno-Arterial extracorporeal membrane oxygenation—a simulation study and case report. *Artif Organs* 41(1):75–81. <https://doi.org/10.1111/aor.12700>
  22. Frenckner B, Broman M, Broomé M (2018) Position of draining venous cannula in extracorporeal membrane oxygenation for respiratory and respiratory/circulatory support in adult patients. *Crit Care* 22(1):163. <https://doi.org/10.1186/s13054-018-2083-0>
  23. Falk L, Hultman J, Broman LM (2023) Differential hypoxemia and the clinical significance of venous drainage position during extracorporeal membrane oxygenation. *Perfusion* 38(4):818–825. <https://doi.org/10.1177/02676591221090667>
  24. Asija R, Fried JA, Siddall EC, Mullin DA, Agerstrand CL, Brodie D, Sonett JR, Lemaitre PH, Abrams D (2023) How I manage differential gas exchange in peripheral venoarterial extracorporeal membrane oxygenation. *Crit Care* 27(1):408. <https://doi.org/10.1186/s13054-023-04703-3>
  25. Biscotti M, Bacchetta M (2014) The “sport model”: extracorporeal membrane oxygenation using the subclavian artery. *Ann Thorac Surg* 98(4):1487–1489. <https://doi.org/10.1016/j.athoracsur.2014.02.069>
  26. Chicotka S, Rosenzweig EB, Brodie D, Bacchetta M (2017) The “Central Sport Model”: extracorporeal membrane oxygenation using the innominate artery for smaller patients as bridge to lung transplantation. *ASAIO J* 63(4):e39–e44. <https://doi.org/10.1097/MAT.0000000000000427>
  27. Rodriguez ML, Maharajh G (2018) Long venous cannula on the arterial position for VA-ECMO. *Perfusion* 33(6):423–425. <https://doi.org/10.1177/0267659118765628>
  28. Antonucci ME, De Paulis S, Bevilacqua F, Calabrese M, Arlotta G, Scapigliati A, Corrado M, Guarneri S, Martinelli L, Zamparelli R, Cavaliere F (2019) Unconventional cannulation strategy in peripheral extracorporeal membrane oxygenation to achieve central perfusion and prevent differential hypoxia. *J Cardiothorac Vasc Anesth* 33(5):1367–1369. <https://doi.org/10.1053/j.jvca.2018.07.016>
  29. Zakhary B, Vercaemst L, Mason P, Antonini MV, Lorusso R, Brodie D (2020) How I approach membrane lung dysfunction in patients receiving ECMO. *Crit Care* 24(1):671. <https://doi.org/10.1186/s13054-020-03388-2>