






















Cite this article as: Bertolaccini L, Abu Akar F, Aigner C, Brunelli A, Decker G, Fang W *et al.* Optimal planning and management strategies for minimally invasive lung segmentectomies: an international Delphi consensus report. *Eur J Cardiothorac Surg* 2024; doi:10.1093/ejcts/ezae351.

# Optimal planning and management strategies for minimally invasive lung segmentectomies: an international Delphi consensus report

Luca Bertolaccini <sup>a,\*</sup>, Firas Abu Akar <sup>b,c,†</sup>, Clemens Aigner <sup>d,†</sup>, Alessandro Brunelli <sup>e,†</sup>,  
Georges Decker <sup>f,†</sup>, Wentao Fang <sup>g,†</sup>, József Furák <sup>h,†</sup>, Mahmoud Ismail <sup>i,†</sup>, Marcelo Jiménez <sup>j,†</sup>,  
Andreas Kirschbaum <sup>k,†</sup>, Marko Kostic <sup>l,†</sup>, Marco Lucchi <sup>m,†</sup>, Shehab Mohamed <sup>n,†</sup>, Sudish C. Murthy <sup>o,†</sup>,  
Calvin S.H. Ng <sup>p,†</sup>, Heribert Ortlieb <sup>q,†</sup>, Nuria Novoa <sup>r,†</sup>, Elena Prisciandaro <sup>s,†</sup>, Lorenzo Spaggiari <sup>a,t,†</sup>,  
Paula A. Ugalde Figueroa <sup>u,†</sup> and Francesco Zaraca <sup>v</sup>

<sup>a</sup>Department of Thoracic Surgery, IEO, European Institute of Oncology, IRCCS, Milan, Italy

<sup>b</sup>Department of Thoracic Surgery, The Edith Wolfson Medical Center, Holon, Center District, Holon, Israel, Affiliated to the Sackler Faculty of Medicine, Tel Aviv University, Tel Aviv, Israel

<sup>c</sup>Honorary Research Affiliate, Department of General Surgery, Faculty of Medicine, Al-Quds University, East Jerusalem, Palestine

<sup>d</sup>Department of Thoracic Surgery, Medical University of Vienna, Wien, Austria

<sup>e</sup>Department of Thoracic Surgery, St. James's University Hospital, Leeds, UK

<sup>f</sup>Department of Thoracic Surgery, Hôpitaux Robert Schuman–Zithaklinik, Luxembourg, Luxembourg

<sup>g</sup>Department of Thoracic Surgery, Shanghai Chest Hospital, Shanghai Jiao Tong University School of Medicine, Shanghai, China

<sup>h</sup>Department of Surgery, University of Szeged, Szeged, Hungary

<sup>i</sup>Department of Thoracic Surgery, Klinikum Ernst von Bergmann, Potsdam, Germany

<sup>j</sup>Department of Thoracic Surgery, Salamanca University Hospital, Salamanca, Spain

<sup>k</sup>Department of Visceral, Thoracic and Vascular Surgery, University of Marburg, Marburg, Germany

<sup>l</sup>Clinic for Thoracic Surgery, University Clinical Centre of Serbia, University of Belgrade, Belgrade, Serbia

<sup>m</sup>Division of Thoracic Surgery, Department of Surgical, Medical and Molecular Pathology and Critical Care Medicine, University of Pisa, Pisa, Italy

<sup>n</sup>Department of Cardiothoracic Surgery, University of Pittsburgh Medical Centre, Pittsburgh, PA, USA

<sup>o</sup>Division of Thoracic and Cardiovascular Surgery, Cleveland Clinic, Cleveland, OH, USA

<sup>p</sup>Division of Cardiothoracic Surgery, Department of Surgery, Prince of Wales Hospital, The Chinese University of Hong Kong, Prince of Wales Hospital, Shatin, New Territories, Hong Kong, China

<sup>q</sup>Department of Thoracic Surgery, Klinikum Mittelbaden, Baden-Baden, Germany

<sup>r</sup>Department of Thoracic Surgery, Hospital Universitario Puerta De Hierro Majadahonda, Madrid, Spain

<sup>s</sup>Division of Thoracic Surgery, Hôpital Erasme, Université Libre de Bruxelles, Brussels, Belgium

<sup>t</sup>Department of Oncology and Hemato-Oncology, University of Milan, Milan, Italy

<sup>u</sup>Division of Thoracic Surgery, Brigham and Women's Hospital, Harvard University, Cambridge, Boston, MA, USA

<sup>v</sup>Department of Vascular and Thoracic Surgery, Regional Hospital, Bolzano, Italy

\* Corresponding author. Department of Thoracic Surgery, IEO, European Institute of Oncology, IRCCS, Via Ripamonti 435, 20141 Milan, Italy.  
Tel: +39-02-57489665; fax: +39-02-56562994; e-mail: luca.bertolaccini@gmail.com (L. Bertolaccini).

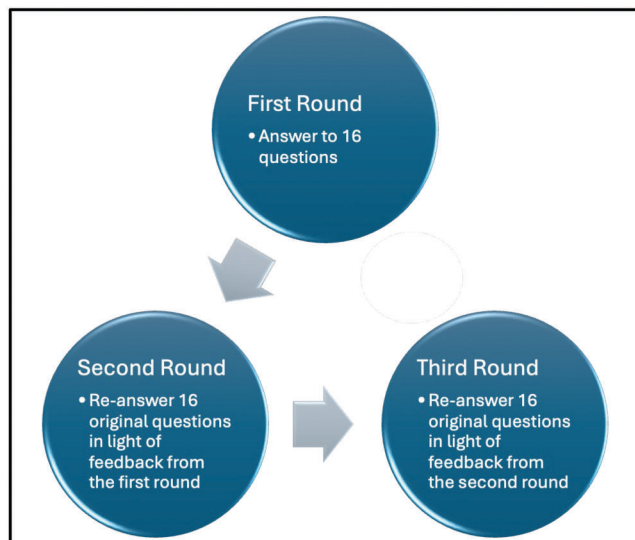
Received 9 May 2024; received in revised form 8 September 2024; accepted 24 September 2024

<sup>†</sup>These authors contributed equally to this article.

## Optimal Planning and Management Strategies for Minimally Invasive Lung Segmentectomies: An International Delphi Consensus Report

### Summary

In a panel of 21 thoracic surgeons, 3-D chest CT reconstructions (Intervention) were recommended before complex MIS in early-stage NSCLC (Population), improving preoperative planning compared to standard methods (Comparison). These strategies could improve safety and precision (Outcome) but do not reduce air leaks or stapler use.



Legend: 3-D = three-dimensional; CT = computed tomography; MIS = minimally invasive segmentectomies; NSCLC = non-small cell lung cancer

### Abstract

**OBJECTIVES:** CALGB140503/JCOG0802 RCTs comparing lobectomy with sublobar resection in stage IA NSCLC have confirmed the non-inferiority of segmentectomy. Additional insight is needed to improve preoperative work-up and intraoperative strategies to increase safety and promote the dissemination of minimally invasive segmentectomy (MIS). A Delphi panel study assessed the level of consensus among surgeons for the planning and management of MIS.

**METHODS:** Twenty-one expert lung surgeons represented academic institutions, major teaching hospitals, and community hospitals from Europe, North America, and Asia. A 3-round Delphi methodology was used to analyse the answers of each panellist. Recognizing that questions with fewer response options have a higher consensus probability due to limited variability, weighted consensus thresholds were modified based on the number of response options.

**RESULTS:** The 21 panellists responded to all 3 rounds of questions. Based on the most robust consensus (94.4%), 3D chest CT reconstructions are recommended only when planning complex segmentectomies. Surgeons should perform 3D reconstructions chest CT scans (consensus = 83.3%). The most effective and safest technique is image-guided VATS in a hybrid operating room (consensus = 83.3%). Dyes with intravenous administration are the safest technique for identifying the intersegmental plane during MIS (consensus = 72.2%). Augmented/mixed reality will probably not immediately help reduce perioperative complications (consensus = 72.2%).

**CONCLUSIONS:** This Delphi consensus supports 3D reconstructions and preoperative pulmonary nodule localization before complex MIS. These recommendations should be considered when allocating resources to improve MIS's safety and oncologic efficacy for patients with small, early-stage lung cancers.

**Keywords:** Lobectomy • Segmentectomy • Lung cancer • 3D reconstruction • Consensus • Delphi methodology

### ABBREVIATIONS

|       |   |
|-------|---|
| 3D    | 3-Dimensional                           |
| CT    | Computed tomography                     |
| MIS   | Minimally invasive segmentectomy        |
| NSCLC | Non-small cell lung cancer              |
| RCT   | Randomized controlled trial             |
| ROC   | Receiver-operating characteristic curve |
| VATS  | Video-assisted thoracic surgery         |

### INTRODUCTION

Surgical resection remains the optimal treatment of early-stage non-small-cell lung cancer (NSCLC). In recent years, segmentectomy has emerged as a viable alternative to lobectomy for selected patients with tumours of 2 cm or ground-glass opacities. Compared to lobectomy, segmentectomy allows greater parenchymal preservation and potentially minimizing functional impairment postoperative complications. However, the surgical technique for segmentectomy is not standardized and is widely debated [1–3].

The North American Lung Cancer Study Group findings from 26 years ago indicated that lobectomy yielded higher overall survival rates for early-stage NSCLC patients than anatomical or non-anatomical segmentectomy [4]. Consequently, lobectomy has become the standard of care for early lung cancer treatment. The Japanese randomized controlled trial (RCT) JCOG0802/WJOG4607L was the first phase III study to demonstrate longer overall survival after segmentectomy than after lobectomy [5]. Effective therapeutic strategies for clinical stage T1a N0 NSCLC include sublobar resections such as non-anatomical segmentectomy and anatomical segmentectomy, as indicated by the CALGB 140503 trial. While these findings suggest that sublobar resections may offer equivalent or superior survival rates compared to lobectomy, a higher loco-regional recurrence rate was associated with sublobar resection [6]. The JCOG0802/WJOG4607L trial observed 6.9% versus 3.1% loco-regional recurrences after sublobar resection, showing a disparity in oncological outcomes [5].

Moreover, within the CALGB 140503 trial, the sublobar resection group exhibited a 13.4% incidence of loco-regional recurrences (lung or hilar lymph nodes of the index lobe) compared to 10% in the lobectomy group. However, this difference did not reach statistical significance [6]. Therefore, whether anatomical segmentectomy should be preferred to lobectomy in patients with stage I disease remains controversial [7]. Given this potential paradigm change, additional insight to optimise preoperative work-up and intraoperative strategy is needed to improve safety and allow for the dissemination of minimally invasive segmentectomy (MIS).

This modified Delphi process aimed to reach a consensus among surgeons regarding MIS planning on the usefulness of 3-dimensional (3D) reconstructions of bronchovascular structures on preoperative chest computed tomography (CT) to assist clinicians before a case of preoperative nodule localization.

## MATERIALS AND METHODS

### Ethics statement

No confidential information was solicited for this study. The IEO, European Institute of Oncology IRCCS's Ethical Committee has exempted the requirement for explicit consent, reasoning that the undertaken activities fall within the scope of routine care.

### Methods

The panel consisted of 21 thoracic surgeons invited to participate in the project voluntarily and based on a systematic search and personal knowledge of L.B. and F.Z. related to previous MIS projects. The selection criteria have focused on ensuring a broad range of expertise and geographical diversity, potentially formed through affinity or network opportunities among professionals known for their significant contributions and expertise in thoracic surgery. The members were drawn from academic centres and tertiary and quaternary hospitals across Europe, North America, the Middle East, and Asia to encourage diverse representation. The group composition aimed to mitigate gender bias and seniority levels, with consensus achieved among all participants regarding their involvement. Through the Delphi methodology, which ensures participant anonymity to prevent any expert from dominating the

**Table 1:** Questions answered by Delphi panel

1. When planning an MIS, do you deem 3D reconstructions of broncho-vascular structures necessary on preoperative chest CT?
2. When planning an MIS, who do you think should perform 3D reconstructions of broncho-vascular structures on preoperative chest CT?
3. Can 3D reconstructions of broncho-vascular structures on preoperative chest CT help prevent major intraoperative complications during MIS?
4. Can 3D reconstructions of broncho-vascular structures on preoperative chest CT help reduce the operating time of MIS?
5. Can 3D reconstructions of broncho-vascular structures on preoperative chest CT help improve oncological radicality during MIS?
6. Can 3D reconstructions improve the management of air leaks during MIS?
7. Can the implementation of 3D reconstructions reduce the need for additional staplers through more precise preoperative planning?
8. In case of difficult localization of small and deep pulmonary nodules (pure or partial ground-glass opacities, solid nodules) where surgical excisional biopsy is indicated, which method of preoperative nodule localization do you prefer?
9. Do you consider preoperative nodule localization necessary before performing a segmentectomy?
10. Who should perform preoperative pulmonary nodule localization?
11. What is the most effective and safest preoperative pulmonary nodule localization technique?
12. Can image-guided VATS in a hybrid operating room help reduce complications during segmentectomy?
13. Can image-guided VATS in a hybrid operating room help reduce the operating time of segmentectomy?
14. Can image-guided VATS in a hybrid operating room help improve oncological radicality during segmentectomy?
15. What is the safest technique for identifying the intersegmental plane during segmentectomy?
16. Can augmented and mixed reality applied to MIS help reduce perioperative complications?

MIS: minimally invasive segmentectomies; VATS: video-assisted thoracic surgery.

process, the group engaged in iterative rounds to foster consensus and provide precise feedback on individual responses. While the ideal number of participants for this method remains undetermined, the selection of experts was based on prior experiences and anticipated response rates [8]. L.B. and F.Z. formulated questions without prior disclosure to the experts (Table 1). The covered topics include the use and need for 3D CT reconstructions in MIS planning, the responsibility for conducting 3D reconstructions, the role of 3D reconstructions in preventing intraoperative complications, the potential impact of 3D reconstructions on reducing operating time, enhancing oncological outcomes, improving the management of air leaks, and reducing stapler use, various methods of preoperative nodule localization, the importance of preoperative nodule localization in MIS, determining the responsible personnel for preoperative nodule localization, effectiveness and safety considerations of different preoperative nodule localization techniques, benefits of image-guided video-assisted thoracic surgery (VATS) in reducing complications during surgery, impact of image-guided VATS on operating time, enhancing oncological, identifying the safest technique for delineating the intersegmental plane, and the potential role of augmented and mixed reality in minimizing perioperative complications. Each expert received an email invitation to participate in the project. A secure link to an external webpage was provided. A 16-question survey was embedded into the webpage, which was managed by L.B. Three rounds of voting were conducted to ensure the integrity of the process. Invitations for each round were sent in October, November, and December 2023,

with reminders to encourage participation. Although surgeons could choose different responses in each round, the structured and iterative nature of the Delphi methodology inherently encourages convergence towards a consensus. In each round, participants reviewed anonymized feedback from their peers, which allowed them to reconsider their initial positions based on the collective insights of the panel. This iterative approach is designed to refine opinions and achieve a more stable consensus. Experts remained unaware of each other's responses throughout the process, with anonymous tabulation of results into a central database managed by L.B. The outcomes of the third round formed the foundation for the current consensus.

## Statistical analysis

Descriptive statistics were used to synthesize the findings, and a de-identified summary was shared with participants before subsequent survey rounds. Participants were encouraged to factor in the responses of their peers when providing feedback in each round of iteration. The distribution of scores for all parameters was assessed. Consensus was usually defined when more than 50% of the panel reached an agreement [8]. However, recognizing that questions with fewer response options have a higher consensus probability due to limited variability, the consensus thresholds were modified based on the number of response options. For questions with three options, clinical practices were recommended if 70–90% of experts agreed, and practices were strongly recommended with a consensus of more than 90%. A weighted threshold was introduced for questions with four or more options to account for increased response variability. Clinical practice was recommended for four-option questions with 65–85% consensus, while strong recommendations required more than 85%. In questions with five or more options, clinical practice was recommended with 60–80% consensus, while strong recommendations required a consensus of more than 80% [9]. Due to the limited number of respondents, a subgroup analysis was not feasible. To avoid blank values, answering all questions was made mandatory. Categorical data were presented as frequencies, numbers, and percentages. Owing to the small number of expert participants, ceiling effects could not be evaluated. Data collection was conducted prospectively.

For statistical analysis, the *standard*, *EZR*, *irr*, *rcmdr*, and *ROC* packages were used in RStudio (R Version 4.1.2, Bird Hippie) [10, 11].

## RESULTS

Overall, 21 experts from 14 countries completed all three rounds of questionnaires. Based on the assessments provided, Delphi produced several recommendations regarding the use of 3D chest CT reconstructions and preoperative nodule localization techniques in thoracic surgery. The recommendations were based on the weighted consensus, where the percentages required for consensus were based on the number of available response options (Table 2).

First and foremost, with a score of 94.4%, 3D chest CT reconstructions were strongly advised, specifically before complex segmentectomies. Preoperative nodule localization was recommended before complex segmentectomies (88.9% consensus). In addition to preoperative planning, the incorporation of 3D chest

**Table 2:** Summary table of recommendations

| Statement   | Score (%) | Clinical practice    |
|---|-----------|----------------------|
| Only before complex segmentectomies 3D reconstructions of broncho-vascular structures on preoperative chest CT is necessary                         | 94.4      | Strongly recommended |
| Thoracic surgeons should perform 3D reconstructions of broncho-vascular structures on preoperative chest CT when planning an MIS                    | 83.3      | Recommended          |
| 3D reconstructions of broncho-vascular structures on preoperative chest CT help improve oncological radicality during MIS                           | 72.2      | Recommended          |
| 3D reconstructions do not improve the management of air leaks during MIS  | 88.9      | Recommended          |
| The implementation of three-dimensional reconstructions does not reduce the need for additional staplers through more precise preoperative planning | 72.2      | Recommended          |
| Only during complex segmentectomies preoperative nodule localisation is necessary   | 88.9      | Recommended          |
| Radiologists and thoracic surgeon should perform preoperative pulmonary nodule localization   | 72.2      | Recommended          |
| Image-guided VATS in a hybrid operating room is the most effective and safest preoperative nodule localization technique                            | 83.3      | Recommended          |
| Only during complex segmentectomies can image-guided VATS in a hybrid operating room help reduce complications.                                     | 72.2      | Recommended          |
| Image-guided VATS in a hybrid operating room help improve oncological radicality during segmentectomy   | 83.3      | Recommended          |
| Identification by dyes with intravenous administration is the safest technique for identifying the intersegmental plane during segmentectomy        | 72.2      | Recommended          |
| Augmented and mixed-reality applied to MIS will probably help reduce perioperative complications, but not in the immediate future                   | 72.2      | Recommended          |

MIS: minimally invasive segmentectomies; VATS: video-assisted thoracic surgery.

CT reconstructions during MIS was encouraged, scoring 83.3%. This combined approach ensures radical tumour resection by providing surgeons with comprehensive anatomical insights while preserving healthy lung tissue.

However, the panellists agreed (88.9%) that the implementation of 3D reconstructions and image-guided VATS does not affect the incidence (or management) of air leaks. While these techniques improve preoperative planning, alternative strategies may be required to manage intraoperative air leaks successfully.

Concerning the practical benefits of implementing 3D technology in MIS planning, 72.2% of panellists agreed that 3D reconstructions would not reduce the consumption of cartridges of rechargeable stapling devices and the judicious use of resources to optimize healthcare costs.

Experts also agreed (72.2%) that both radiologists and thoracic surgeons should perform preoperative pulmonary nodule localization (72.2% consensus). The implementation of image-guided VATS in a hybrid operating room was endorsed by 72.2%



consensus by experts, improving the accuracy of lesion localization and minimizing the risk of procedural complications.

Lastly, while the use of augmented and mixed-reality technologies in MIS shows promise in reducing perioperative complications, the panellists acknowledged that most (72.2% consensus) agreed that significant advancements are needed before widespread implementation (72.2% consensus).

## DISCUSSION

Owing to the widespread use of low-dose spiral CT, early detection of pulmonary lesions has increased. It has been shown that early diagnosis of lung cancer improves the 5-year survival of screened cases [12, 13]. Since the accuracy of imaging techniques is still limited, preoperative pathological diagnosis is often deemed necessary for suspicious lung nodules by needle biopsy. In selected patients with peripheral, node-negative lung cancer, segmentectomy up to 2 cm NSCLC sublobar resection has emerged as a valid curative alternative to lobectomy [5, 6]. This evolution poses two challenges to thoracic surgeons: (i) the number of simple and complex pulmonary segmentectomies is increasing; (ii) the number of small pulmonary nodules, which are difficult to define and localize, is increasing. The study's use of the terms complex and simple segmentectomies reflects an attempt to categorize different MIS procedures based on their perceived difficulty and anatomical and technical challenges. However, there is currently no universally accepted consensus on the precise definitions of these terms [2]. In general surgical practice, complex segmentectomies are often characterized by anatomical challenges that include procedures involving multiple segments, deep-seated lesions, or segments with challenging anatomical variations, a technical difficulty that refers to cases where intricate dissection around critical structures such as blood vessels and bronchi is required; larger tumours, located deeper within the lung tissue, or situated close to vital structures may necessitate more complex surgical techniques.

Conversely, simple segmentectomies typically involve more straightforward anatomical regions, with less challenging dissections and easier access to the target segments. These procedures are generally performed for smaller, peripheral tumours that are more easily accessible. Since there is no standardized definition, the classification was likely based on the expert panel's collective experience and the specific context of the procedures discussed in the Delphi survey [14].

This modified Delphi initiative aimed to reach a consensus on the usefulness of 3D chest CT reconstructions to assist clinicians before an MIS and the potential of using the hybrid operating room in case of difficult localization of small and deep pulmonary nodules. It is strongly recommended to use 3D chest CT reconstructions before complex segmentectomies. The PATCHES study will demonstrate whether 3D reconstructions could be helpful even before simple MIS [15, 16]. The panellists agreed that thoracic surgeons should obtain 3D reconstructions preoperatively. Today, thoracic surgeons should be trained to interpret (and ideally perform preoperative 3D reconstructions) on a routine basis scan. In our survey, the panellists agreed that preoperative 3D reconstruction could help ensure R0 resections, reduce complication rates during complex MIS, and shorten operation times, as demonstrated by previous retrospective studies [17]. Other interesting uses of 3D reconstruction include surgical training and preoperative patient counselling [18–21].

However, according to most respondents, 3D reconstructions do not improve air leak management during MIS or reduce the consumption of cartridges of rechargeable stapling devices. A subsequent study (PATCHES) will verify these aspects [15, 22]. Our experts recommend that radiologists or thoracic surgeons perform 3D reconstructions on CT scans. Collaborative efforts between these specialities may ensure a more comprehensive evaluation and accurate localization of pulmonary lesions, thereby increasing the overall success rate of MIS.

Including the opinion of experts on the potential benefits of 3D planning in the learning curve for complex segmentectomy can provide valuable insights into its role in surgical education and skill acquisition. This aspect highlights how advanced imaging technologies may facilitate the training and development of thoracic surgeons underlying the current utility of 3D planning in clinical practice and its potential long-term impact on the training and expertise of future thoracic surgeons.

Preoperative nodule localization was strongly recommended only for complex segmentectomies. The intraoperative identification of small solid nodules, especially if smaller than 2 cm and with a distance of more than 8 mm from the pleural surface, poses a non-negligible challenge, especially during minimally invasive procedures and ground glass lesions [23, 24]. While various nodule localization approaches have been described, the reported techniques have yet to be shown to outperform the others [25]. Typically, resource availability and institutional experience guides mainly affect the choice of the localization strategy. There was a high agreement that image-guided VATS should be ideally used in a hybrid operating room and was considered the most effective and safest technique for preoperative nodule localization (83.3% consensus). This approach combines advanced imaging technology with accurate intraoperative guidance, allowing the performance of thoracoscopic wedge resections or segmentectomies of nonpalpable lung nodules [26–29]. The panellists agreed that image-guided VATS could help prevent complications during complex segmentectomies, reduce operative time and improve oncological radicality during MIS. The available evidence supports this [14]. Even if there are different localization techniques, such as radiotracer, dye, or Pafolacianine injection, the intravenous administration of indocyanine green was considered the safest technique to determine the intersegmental plane during MIS. A recent review of the literature confirms our recommendation [30]. Other technological supports related to artificial intelligence have recently been introduced into clinical practice, such as augmented and mixed reality applied to MIS [31, 32]. The preliminary results are encouraging and promise further improvements, especially in teaching. The panellists agreed that augmented and mixed reality applied to MIS may help prevent perioperative complications, but not in the immediate future.

Including diverse perspectives ensures that the consensus is not biased towards the practices and preferences of a homogenous group of specialists. In VATS segmentectomy, thoracic surgeons who rely on traditional imaging techniques and radiologists, anaesthesiologists, and surgical technologists can offer valuable input. This multidisciplinary approach can highlight potential limitations, operational challenges, and areas where 3D reconstruction might not be necessary or beneficial. For example, radiologists could assess the imaging technology's accuracy and reliability objectively, while anaesthesiologists could discuss its implications on perioperative care. Additionally, thoracic surgeons who do not use 3D reconstructions might offer alternative strategies that are equally effective

but less resource-intensive. This diversity in expertise can lead to more robust, comprehensive, and practical guidelines. Therefore, future consensus studies on VATS segmentectomy should consider including a more extensive array of experts to ensure that the conclusions drawn are well-rounded and objectively reflect the current state of practice across different settings. This approach will contribute to more effective and widely applicable guidelines for minimally invasive lung segmentectomies.

In the context of MIS, it is essential to acknowledge that, despite technological advancements and preoperative planning tools, human skill and surgeon experience remain fundamental in determining the appropriate resection to perform. This aspect should be underscored to provide a holistic view of the factors contributing to successful surgical outcomes. While 3D reconstructions and other advanced imaging techniques offer significant benefits in preoperative planning and intraoperative navigation, they cannot replace the nuanced judgement and skill that experienced surgeons bring to the operating table. The ability to interpret imaging data, adapt to intraoperative findings, and make real-time decisions are skills honed through years of practice and can only be partially supplanted by technology. Surgeons must integrate their clinical knowledge, tactile feedback, and situational awareness with the information provided by advanced imaging tools to achieve optimal results. For instance, identifying and preserving vital structures, managing unexpected anatomical variations, and ensuring complete resection while minimizing damage to healthy tissue rely heavily on a surgeon's expertise and experience. Therefore, while promoting 3D reconstructions and other technological advancements, it is crucial to emphasize that these tools should augment, not replace, the surgeon's expertise. Training programs should continue to focus on developing these fundamental surgical skills alongside teaching the effective use of new technologies. This integrated approach will ensure that surgeons can leverage their skills and technological aids to enhance patient outcomes [31].

3D planning and reconstruction technologies offer significant advantages in preoperative and intraoperative guidance, especially for complex segmentectomies. However, these advanced imaging techniques come with substantial costs. The software and hardware required for generating high-quality 3D reconstructions are expensive, and the process often requires additional time and expertise from radiologists and thoracic surgeons. This can increase operational costs for healthcare institutions, which may only be feasible for some facilities, especially those with limited budgets. The cost of implementing 3D planning includes the initial investment in technology and ongoing expenses such as maintenance, software updates, and personnel training. Smaller hospitals and clinics, particularly in resource-constrained settings, may find it challenging to justify these expenses, especially if the volume of segmentectomy procedures performed is low. Given these financial considerations, it may be more practical to recommend 3D planning selectively rather than routinely. Prioritizing 3D reconstructions for complex segmentectomies, as suggested by the Delphi consensus, can help optimize resource allocation. By focusing on cases where the benefits of 3D planning are most pronounced, institutions can balance the need for advanced preoperative planning with budgetary constraints. Furthermore, cost-effectiveness studies are needed to evaluate the long-term benefits of 3D planning in terms of improved surgical outcomes, reduced complication rates, and potential savings from shorter operative times and fewer postoperative complications. These studies could provide a more comprehensive understanding of the financial impact and help justify the investment in 3D planning technologies [33, 34].

Navigational bronchoscopy, including its robotic-assisted variant, significantly advances the localization and biopsy of pulmonary nodules, especially those small or deep within the lung. These techniques use electromagnetic navigation or robotic systems to guide tools to the target nodule with high precision, enhancing diagnostic yield and aiding preoperative planning by placing fiducials or markers for accurate intraoperative localization. However, these procedures are costly, have a steep learning curve, and are only widely available in some medical centres. Using metal clips for preoperative localization involves placing clips near the target nodule under imaging guidance [35]. This technique provides immediate visual feedback during surgery, facilitating precise nodule localization. It is more cost-effective and straightforward than advanced navigational systems, but it carries risks such as clip migration, complications like pneumothorax or bleeding, and additional radiation exposure. Incorporating these localization techniques into minimally invasive segmentectomy planning can enhance accuracy and safety. Navigational bronchoscopy is particularly beneficial for deep-seated nodules. At the same time, metal clips are effective for peripheral lesions. The Delphi consensus supports using advanced imaging and localization techniques like 3D reconstructions and image-guided VATS to improve MIS outcomes. Integrating navigational bronchoscopy and metal clips into this framework provides additional tools for optimizing preoperative planning and intraoperative precision. However, cost, learning curve, and availability considerations must be addressed to maximize their clinical utility [36, 37].

The Delphi method relies on a structured process to gather expert opinions and reach a consensus, rather than traditional hypothesis testing, which makes statistical power assessments somewhat different from those in other study designs. In conventional studies, statistical power refers to the probability of correctly rejecting a false null hypothesis. However, a Delphi study focuses on achieving consensus among experts rather than testing specific hypotheses. The sample size is relatively small since the panel comprised 21 thoracic surgeons from various geographical regions and esteemed institutions. While the Delphi method does not have a universally agreed-upon optimal sample size, this number can still be considered sufficient for achieving expert consensus, as prior studies suggest that panels of 10–30 experts can provide reliable results [8, 38]. Another consideration is the predefined consensus threshold of >50% for agreement. Consensus was established when more than 50% of the panel reached agreement. However, recognizing that questions with fewer response options have a higher consensus probability due to limited variability, the consensus threshold was modified based on the number of response options. While these thresholds are practical for achieving actionable consensus, they do not provide the same rigorous statistical validation as p-values and confidence intervals in traditional studies. Therefore, while the study successfully identifies areas of agreement among a selected group of experts, the strength and applicability of these recommendations might be influenced by the subjective nature of the consensus process and the relatively small and potentially non-representative sample size [39, 40].

## Limitations

This study has several limitations.

First, the high response rate of this Delphi panel may be attributable to a selection bias, as all the experts have a keen interest in this subject. In addition, the knowledge that participating

in the Delphi survey would lead to authorship may have represented a motivation for completion. However, it is essential to acknowledge a potential selection bias in assembling a group of experts with similar interests and opinions, which could impact the generalizability of the conclusions.

Secondly, the reliance on online systems for data collection precluded in-person interaction with participants. The virtual setting may have hindered participants' ability to fully express themselves or engage in meaningful dialogue, which could have influenced the validity and reliability of the data collected.

Notably, the absence of experts from the African continent and significant contributive countries such as Japan, Poland, France, and Denmark presents an explicit limitation. These omissions could impact the generalizability and comprehensiveness of the study's conclusions. The absence of perspectives from these unrepresented regions and prestigious institutions means that certain practices, insights, and innovations in those areas might have yet to be considered, potentially skewing the consensus towards practices and perspectives dominant in the regions represented.

Lastly, the conclusions drawn from the Delphi initiative could have been more representative of the variability of the Consensus group if additional options had been included or if respondents had been given the opportunity for open-ended responses. Therefore, caution should be exercised when interpreting the findings of this survey.

## CONCLUSIONS

The consensus reached through this Delphi initiative advocates for the use of 3-D reconstructions and preoperative pulmonary nodule localization before complex MIS. These recommendations may urge hospital management divisions to allocate resources to enhance the safety and oncological outcomes of MIS.

## SUPPLEMENTARY MATERIAL

[Supplementary material](#) is available at *EJCTS* online.

## FUNDING

This work was partially supported by the Italian Ministry of Health with *Ricerca Corrente* and *5x1000* funds.

**Conflict of interest:** Alessandro Brunelli—Advisory Board and consultancy fee with Astra Zeneca, BMS, MSD, Ethicon, Medtronic, and Roche. Paula A. Ugalde Figueroa—Advisory Board and consultancy fee with AstraZeneca, BMS, MSD and Medtronic. Other authors have no conflict of interest to declare.

## DATA AVAILABILITY

The corresponding author will share the data underlying this article at a reasonable request.

## Author contributions

**Luca Bertolaccini:** Conceptualization; Formal analysis; Methodology; Validation; Writing—original draft; Writing—review & editing. **Firas Abu Akar:**

Investigation; Writing—original draft; Writing—review & editing. **Clemens Aigner:** Conceptualization; Writing—original draft; Writing—review & editing. **Alessandro Brunelli:** Investigation; Writing—original draft; Writing—review & editing. **Georges Decker:** Writing—original draft; Writing—review & editing. **Wentao Fang:** Conceptualization; Investigation; Writing—original draft; Writing—review & editing. **József Furák:** Investigation; Writing—original draft; Writing—review & editing. **Mahmoud Ismail:** Investigation; Writing—original draft; Writing—review & editing. **Marcelo Jiménez:** Investigation; Writing—original draft; Writing—review & editing. **Andreas Kirschbaum:** Investigation; Writing—original draft; Writing—review & editing. **Marko Kostic:** Investigation; Writing—original draft; Writing—review & editing. **Marco Lucchi:** Investigation; Writing—original draft; Writing—review & editing. **Shehab Mohamed:** Investigation; Writing—original draft; Writing—review & editing. **Sudish C. Murthy:** Investigation; Writing—original draft; Writing—review & editing. **Calvin S.H. Ng:** Investigation; Writing—original draft; Writing—review & editing. **Heribert Ortlieb:** Investigation; Writing—original draft; Writing—review & editing. **Nuria Novoa:** Investigation. **Elena Prisciandaro:** Investigation; Writing—original draft; Writing—review & editing. **Lorenzo Spaggiari:** Investigation; Writing—original draft; Writing—review & editing. **Paula A. Ugalde Figueroa:** Investigation; Writing—original draft; Writing—review & editing. **Francesco Zaraca:** Conceptualization.

## Reviewer information

Reviewer information European Journal of Cardio-Thoracic Surgery thanks Tevfik Kaplan, Mohamed Rahouma, Pascal Alexandre Thomas and the other anonymous reviewers for their contribution to the peer review process of this article.

## REFERENCES

- [1] Bertolaccini L, Cara A, Chiari M, Diotti C, Glick N, Mohamed S *et al.* Real-world survival outcomes of wedge resection versus lobectomy for cT1a/b cN0 cM0 non-small cell lung cancer: a single center retrospective analysis. *Front Oncol* 2023;13:1226429.
- [2] Brunelli A, Decaluwe H, Gonzalez M, Gossot D, Petersen RH, Augustin F *et al.* European Society of Thoracic Surgeons expert consensus recommendations on technical standards of segmentectomy for primary lung cancer. *Eur J Cardiothorac Surg* 2023;63(6):ezad224.
- [3] Caso R, Watson TJ, Tefera E, Cerfolio R, Abbas AE, Lazar JF *et al.* Comparing robotic, thoracoscopic, and open segmentectomy: a National Cancer Database Analysis. *J Surg Res* 2024;296:674–80.
- [4] Ginsberg RJ, Rubinstein LV. Randomized trial of lobectomy versus limited resection for T1 N0 non-small cell lung cancer. Lung Cancer Study Group. *Ann Thorac Surg* 1995;60:615–22. discussion 22–3.
- [5] Saji H, Okada M, Tsuboi M, Nakajima R, Suzuki K, Aokage K *et al.*; West Japan Oncology Group and Japan Clinical Oncology Group. Segmentectomy versus lobectomy in small-sized peripheral non-small-cell lung cancer (JCOG0802/WJOG4607L): a multicentre, open-label, phase 3, randomised, controlled, non-inferiority trial. *Lancet* 2022; 399:1607–17.
- [6] Altorki N, Wang X, Kozono D, Watt C, Landrenau R, Wigle D *et al.* Lobar or sublobar resection for peripheral stage IA non-small-cell lung cancer. *N Engl J Med* 2023;388:489–98.
- [7] D'Amico TA. Japanese Oncology Group 0802: another giant leap. *J Thorac Cardiovasc Surg* 2023;165:873–5.
- [8] Fink A, Kosecoff J, Chassin M, Brook RH. Consensus methods: characteristics and guidelines for use. *Am J Public Health* 1984;74:979–83.
- [9] Lange T, Kopkow C, Lutzner J, Gunther KP, Gravius S, Scharf HP *et al.* Comparison of different rating scales for the use in Delphi studies: different scales lead to different consensus and show different test-retest reliability. *BMC Med Res Methodol* 2020;20:28.
- [10] Team R. RStudio: Integrated Development Environment for R. Boston, MA: RStudio, Inc., 2021.
- [11] Team RC. R: A Language and Environment for Statistical Computing. Vienna, Austria: R Foundation for Statistical Computing, 2021.
- [12] Passiglia F, Cinquini M, Bertolaccini L, Del Re M, Facchinetti F, Ferrara R *et al.* Benefits and harms of lung cancer screening by chest computed tomography: a systematic review and meta-analysis. *J Clin Oncol* 2021; 39:2574–85.
- [13] Bonney A, Malouf R, Marchal C, Manners D, Fong KM, Marshall HM *et al.* Impact of low-dose computed tomography (LDCT) screening on

- lung cancer-related mortality. *Cochrane Database Syst Rev* 2022; 8:CD013829.
- [14] Bertolaccini L, Mohamed S, Diotti C, Uslenghi C, Cara A, Chiari M *et al.* Differences in selected postoperative outcomes between simple and complex segmentectomies for lung cancer: a systematic review and meta-analysis. *Eur J Surg Oncol* 2023;49:107101.
  - [15] Zaraca F, Kirschbaum A, Pipitone MD, Bertolaccini L; PATCHES study group. Prospective randomized study on the efficacy of three-dimensional reconstructions of bronchovascular structures on preoperative chest CT scan in patients who are candidates for pulmonary segmentectomy surgery: the PATCHES (Prospective rAndomized sTudy efficaCy of tHree-dimensional rEconstructions Segmentecomy) study protocol. *Trials* 2023;24:594.
  - [16] Chen D, Zhang X, Mei Y, Liao F, Xu H, Li Z *et al.* Multi-stage learning for segmentation of aortic dissections using a prior aortic anatomy simplification. *Med Image Anal* 2021;69:101931.
  - [17] Vanstraelen S, Rocco G, Park BJ, Jones DR. The necessity of preoperative planning and nodule localization in the modern era of thoracic surgery. *JTCVS Open* 2024;18:347–52.
  - [18] She XW, Gu YB, Xu C, Li C, Ding C, Chen J *et al.* Three-dimensional (3D)- computed tomography bronchography and angiography combined with 3D-video-assisted thoracic surgery (VATS) versus conventional 2D-VATS anatomic pulmonary segmentectomy for the treatment of non-small cell lung cancer. *Thorac Cancer* 2018;9:305–9.
  - [19] Xue L, Fan H, Shi W, Ge D, Zhang Y, Wang Q *et al.* Preoperative 3-dimensional computed tomography lung simulation before video-assisted thoracoscopic anatomic segmentectomy for ground glass opacity in lung. *J Thorac Dis* 2018;10:6598–605.
  - [20] Liu X, Zhao Y, Xuan Y, Lan X, Zhao J, Lan X *et al.* Three-dimensional printing in the preoperative planning of thoracoscopic pulmonary segmentectomy. *Transl Lung Cancer Res* 2019;8:929–37.
  - [21] Qiu B, Ji Y, He H, Zhao J, Xue Q, Gao S. Three-dimensional reconstruction/personalized three-dimensional printed model for thoracoscopic anatomical partial-lobectomy in stage I lung cancer: a retrospective study. *Transl Lung Cancer Res* 2020;9:1235–46.
  - [22] Zaraca F, Kirschbaum A, Pipitone MD, Bertolaccini L; PATCHES study group. Correction: prospective randomized study on the efficacy of three-dimensional reconstructions of bronchovascular structures on preoperative chest CT scan in patients who are candidates for pulmonary segmentectomy surgery: the PATCHES (Prospective rAndomized sTudy efficaCy of tHree-dimensional rEconstructions Segmentecomy) study protocol. *Trials* 2023;24:629.
  - [23] Qiang Y, Zhang L, Yang N, Xu J, Li DM, Lv T *et al.* Diagnostic and therapeutic value of computed tomography guided coil placement after digital subtraction angiography guided video-assisted thoracoscopic surgery resection for solitary pulmonary nodules. *Transl Lung Cancer Res* 2015;4:598–604.
  - [24] Ichinose J, Kohno T, Fujimori S, Harano T, Suzuki S. Efficacy and complications of computed tomography-guided hook wire localization. *Ann Thorac Surg* 2013;96:1203–8.
  - [25] Gilberto GM, Falsarella PM, Andrade JR, Schmid BP, Mariotti GC, Terra RM *et al.* Lung nodule localization in hybrid room before minimally invasive thoracic surgery: series of 20 cases and literature review. *Einstein (Sao Paulo)* 2022;20:eAO6665.
  - [26] Liang CC, Liao CH, Cheng YF, Hung WH, Chen HC, Huang CL *et al.* Bilateral lung nodules resection by image-guided video-assisted thoracoscopic surgery: a case series. *J Cardiothorac Surg* 2020;15:203.
  - [27] Gill RR, Barlow J, Jaklitsch MT, Schmidlin EJ, Hartigan PM, Bueno R. Image-guided video-assisted thoracoscopic resection (iVATS): translation to clinical practice-real-world experience. *J Surg Oncol* 2020; 121:1225–32.
  - [28] Ng CSH, Man Chu C, Kwok MWT, Yim APC, Wong RHL. Hybrid DynaCT scan-guided localization single-port lobectomy [corrected]. *Chest* 2015; 147:e76–8.
  - [29] Fujiwara-Kuroda A, Aragaki M, Hida Y, Ujiie H, Ohtaka K, Shiiya H *et al.* A simple and safe surgical technique for nonpalpable lung tumors: one-stop solution for a nonpalpable lung tumor, marking, resection, and confirmation of the surgical margin in a hybrid operating room (OS-MRCH). *Transl Lung Cancer Res* 2024;13:603–11.
  - [30] Peeters M, Jansen Y, Daemen JHT, van Roozendaal LM, De Leyn P, Hulsewe KWE *et al.* The use of intravenous indocyanine green in minimally invasive segmental lung resections: a systematic review. *Transl Lung Cancer Res* 2024;13:612–22.
  - [31] Sadeghi AH, Maat A, Taverne Y, Cornelissen R, Dingemans AC, Bogers A *et al.* Virtual reality and artificial intelligence for 3-dimensional planning of lung segmentectomies. *JTCVS Tech* 2021;7:309–21.
  - [32] Perkins SL, Krajancich B, Yang CJ, Hargreaves BA, Daniel BL, Berry MF. A patient-specific mixed-reality visualization tool for thoracic surgical planning. *Ann Thorac Surg* 2020;110:290–5.
  - [33] Herrera LJ, Wherley EM, Agyabeng-Dadzie K, Ramsuchit B, Johnston MA, Escalon JC. 500 consecutive robotic lobectomies for non-small cell lung cancer: perioperative and oncologic outcomes. *Innovations (Phila)* 2021;16:441–7.
  - [34] Brunelli A, Pompili C, Dinesh P, Bassi V, Imperatori A. Financial validation of the European Society of Thoracic Surgeons risk score predicting prolonged air leak after video-assisted thoracic surgery lobectomy. *J Thorac Cardiovasc Surg* 2018;156:1224–30.
  - [35] Liam CK, Lee P, Yu CJ, Bai C, Yasufuku K. The diagnosis of lung cancer in the era of interventional pulmonology. *Int J Tuberc Lung Dis* 2021; 25:6–15.
  - [36] Gmehlin CG, Kurman JS, Benn BS. Size and vision: impact of fluoroscopic navigation, digital tomosynthesis, and continuous catheter tip tracking on diagnostic yield of small, bronchus sign negative lung nodules. *Respir Med* 2022;202:106941.
  - [37] Benn BS, Gmehlin CG, Kurman JS, Doan J. Does transbronchial lung cryobiopsy improve diagnostic yield of digital tomosynthesis-assisted electromagnetic navigation guided bronchoscopic biopsy of pulmonary nodules? A pilot study. *Respir Med* 2022;202:106966.
  - [38] Yuan I, Topjian AA, Kurth CD, Kirschen MP, Ward CG, Zhang B *et al.* Guide to the statistical analysis plan. *Paediatr Anaesth* 2019;29:237–42.
  - [39] Ciani O, Manyara AM, Davies P, Stewart D, Weir CJ, Young AE *et al.* A framework for the definition and interpretation of the use of surrogate endpoints in interventional trials. *EClinicalMedicine* 2023;65:102283.
  - [40] Zaraca F, Brunelli A, Pipitone MD, Abdellateef A, Abu Akar F, Augustin F *et al.* A Delphi Consensus report from the “Prolonged Air Leak: A Survey” study group on prevention and management of postoperative air leaks after minimally invasive anatomical resections. *Eur J Cardiothorac Surg* 2022;62(3):ezac211.