

International Consensus Statements on Intraoperative Testing for Cochlear Implantation Surgery

Farid Alzhrani,¹ Isra Aljazeera,^{1,2,42} Yassin Abdelsamad,³ Abdulrahman Alsanosi,¹ Ana H. Kim,⁴ Angel Ramos-Macias,⁵ Angel Ramos-de-Miguel,⁵ Anja Kurz,⁶ Artur Lorens,⁷ Bruce Gantz,⁸ Craig A. Buchman,⁹ Dayse Távora-Vieira,^{10,11,12} Georg Sprinzl,¹³ Griet Mertens,^{14,15} James E. Saunders,¹⁶ Julie Kosaner,¹⁷ Laila M. Telmesani,¹⁸ Luis Lassaletta,^{19,20} Manohar Bance,²¹ Medhat Yousef,^{1,22} Meredith A. Holcomb,²³ Oliver Adunka,²⁴ Per Cayé-Thomasen,²⁵ Piotr H. Skarzynski,^{26,27,28,29} Ranjith Rajeswaran,³⁰ Robert J. Briggs,³¹ Seung-Ha Oh,³² Stefan Plontke,³³ Stephen J. O'Leary,³¹ Sumit Agrawal,^{34,35} Tatsuya Yamasoba,^{36,37} Thomas Lenarz,³⁸ Thomas Wesarg,³⁹ Walter Kutz,⁴⁰ Patrick Connolly,⁴¹ Ilona Anderson,⁴¹ and Abdulrahman Hagr¹

Objectives: A wide variety of intraoperative tests are available in cochlear implantation. However, no consensus exists on which tests constitute the minimum necessary battery. We assembled an international panel of clinical experts to develop, refine, and vote upon a set of core consensus statements.

Design: A literature review was used to identify intraoperative tests currently used in the field and draft a set of provisional statements. For statement evaluation and refinement, we used a modified Delphi consensus panel structure. Multiple interactive rounds of voting, evaluation, and feedback were conducted to achieve convergence.

Results: Twenty-nine provisional statements were included in the original draft. In the first voting round, consensus was reached on 15 statements. Of the 14 statements that did not reach consensus, 12 were revised based on feedback provided by the expert practitioners, and 2 were eliminated. In the second voting round, 10 of the 12 revised statements reached a consensus. The two statements which did not achieve consensus were further revised and subjected to a third voting round. However, both statements failed to achieve consensus in the third round. In addition, during the final revision, one more statement was decided to be deleted due to overlap with another modified statement.

Conclusions: A final core set of 24 consensus statements was generated, covering wide areas of intraoperative testing during CI surgery. These statements may provide utility as evidence-based guidelines to improve quality and achieve uniformity of surgical practice.

Key words: Cochlear implantation, Consensus, Intraoperative testing, Recommendations, Survey.

(Ear & Hearing 2024;XX:00–00)

INTRODUCTION

Cochlear implants (CIs) have been transformative for individuals with severe-to-profound hearing loss over the past several decades, yielding substantial improvements in auditory perception, speech understanding, and quality of life. With the rising numbers of CI surgeries in recent years (Raine 2013; Nassiri et al. 2022), as well as the expansion of candidacy to wider groups (Varadarajan et al. 2020), there is a greater need to standardize and optimize the surgical procedure to ensure consistent and favorable outcomes.

Intraoperative testing is used for several purposes during CI surgery: to evaluate device functionality, to verify the position of the implant and electrode array, and to assess the functional status of the patient's auditory pathway (Wesarg et al. 2014, 2016). These tests include imaging techniques, such as x-ray, computed tomography (CT), and fluoroscopy; electrophysiological and biophysical evaluations, such as measurements of the electrode impedance, electrically evoked compound action potential (ECAP), electrocochleography (ECoChG), electrically evoked auditory brainstem responses (EABRs), and electrically evoked stapedial reflex threshold (ESRT); and other tests like subjective patient responses. There remains a lack of consensus regarding which tests, if any, should be used during surgery,

¹King Abdullah Ear Specialist Center (KAESC), College of Medicine, King Saud University Medical City, King Saud University, Riyadh, Saudi Arabia; ²Aljaber Ophthalmology and Otolaryngology Specialized Hospital, Ministry of Health, Ahssa, Saudi Arabia; ³Research Department, Research Department, MED-EL GmbH, Riyadh, Saudi Arabia; ⁴Columbia University Medical Center, New York, New York, USA; ⁵Department of Otolaryngology and Head and Neck Surgery, University of Las Palmas de Gran Canaria, Las Palmas, Spain; ⁶Department of Oto-Rhino-Laryngology, Plastic, Aesthetic and Reconstructive Head and Neck Surgery, Comprehensive Hearing Center, Würzburg, Germany; ⁷Word Hearing Center, Institute of Physiology and Pathology of Hearing, Warsaw/Kajetany, Poland; ⁸Department of Otolaryngology—Head and Neck Surgery/Neurosurgery, University of Iowa Hospitals and Clinics, University of Iowa, Iowa City, Iowa, USA; ⁹Department of Otolaryngology-Head & Neck Surgery, Washington University in St. Louis, St. Louis, MO.; ¹⁰Division of Surgery, Medical School, The University of Western Australia, Perth, Western Australia, Australia; ¹¹Department of Audiology, Fiona Stanley Fremantle Hospitals Group, Perth, Western Australia, Australia; ¹²School of Population Health, Curtin University, Perth, Western Australia, Australia; ¹³Department of Otorhinolaryngology, Karl Landsteiner University of Health Sciences, University Hospital St. Poelten, St. Poelten, Austria; ¹⁴Department of Otorhinolaryngology, Head and Neck Surgery, Antwerp University Hospital, Antwerp, Belgium; ¹⁵Faculty of Medicine and Health Sciences, Experimental Laboratory of Translational Neurosciences and Dento-Otolaryngology, University of Antwerp, Antwerp, Belgium; ¹⁶Section of Otolaryngology-Head and Neck Surgery, Department of Surgery, Dartmouth-Hitchcock Medical Center, Geisel School of Medicine at Dartmouth, New Hampshire, USA; ¹⁷Meders Speech and Hearing Clinic, Meders İştirak ve Konuşma Merkezi, İstanbul, Turkey; ¹⁸Department of Otolaryngology/Head and Neck Surgery, College of Medicine, Imam Abdulrahman Bin Faisal University, Dammam, Saudi Arabia; ¹⁹Department of Otorhinolaryngology, Hospital La Paz, IdiPAZ Research Institute, Madrid, Spain; ²⁰Biomedical Research Networking Centre on Rare Diseases, Institute of Health Carlos III, Madrid, Spain; ²¹Department of Otolaryngology-Head and Neck Surgery, Addenbrooke's Hospital, University of Cambridge, United Kingdom; ²²Audiology Unit, ENT Department, Menoufia University, Menoufia, Egypt; ²³Hearing Implant Program, Department of Otolaryngology, University of Miami, Miami, Florida, USA; ²⁴Ohio State

and their precise function and utility. The absence of standardized protocols for intraoperative testing poses challenges in the evaluation and comparison of surgical outcomes.

Recognizing this knowledge gap, the present work aimed to generate a comprehensive set of consensus statements regarding intraoperative testing during CI surgery. Establishing such a consensus would be useful for several reasons. First, it would provide a framework for the training of practitioners. Second, it would provide clarity for payers and regulators about which tests are and which are not considered necessary. Third, it would add to the existing best-practice guidelines in the broader CI field. Consensus statements and expert opinions have been generated for other aspects of practice in the CI field, such as candidacy and indications (Ramsden et al. 2012; Buchman et al. 2020), and hearing preservation surgery (Rajan et al. 2017; Topsakal et al. 2022).

To accomplish this, we used a modified Delphi method, which is a well-established technique for obtaining expert consensus on complex issues (Dalkey & Helmer 1963; Meshkat et al. 2014). The Delphi method uses iterative rounds of voting, evaluation, and feedback, allowing for the refinement and convergence of opinions over multiple iterations. By using this method, we aimed to achieve a high level of agreement among the participating experts regarding the selection, implementation, and interpretation of intraoperative tests. The output of this work is a core set of consensus statements on intraoperative testing. This paper documents the process for generation, evaluation, and voting of the consensus statements on intraoperative testing, and presents the final list of intraoperative testing statements.

University Wexner Medical Center, The Ohio State University, Columbus, Ohio, USA; ²⁵Department of Otorhinolaryngology, Head and Neck Surgery and Audiology, Rigshospitalet, Denmark; ²⁶Department of Teleaudiology and Screening, World Hearing Center, Institute of Physiology and Pathology of Hearing, Warsaw, Poland; ²⁷Faculty of Dental Medicine, Heart Failure and Cardiac Rehabilitation Department, Medical University of Warsaw, Warsaw, Poland; ²⁸Institute of Sensory Organs, Nadarzyn/Kajetany, Poland; ²⁹Center of Hearing and Speech “Medicus,” Nadarzyn/Kajetany, Poland; ³⁰Madras ENT Research Foundation MERF Institute of Speech and Hearing, Chennai, India; ³¹Department of Surgery, Otolaryngology, The University of Melbourne, The Royal Victorian Eye and Ear Hospital, East Melbourne, Victoria, Australia; ³²Department of Otorhinolaryngology, Seoul National University College of Medicine, Seoul, Korea; ³³Department of Otorhinolaryngology, Head and Neck Surgery, Martin Luther University Halle-Wittenberg, Halle (Saale), Germany; ³⁴Department of Otolaryngology-Head and Neck Surgery, Western University, London, Ontario, Canada; ³⁵Department of Electrical and Computer Engineering, School of Biomedical Engineering, Western University, London, Ontario, Canada; ³⁶Tokyo Teishin Hospital, Tokyo, Japan; ³⁷Department of Otolaryngology and Head and Neck Surgery, University of Tokyo, Tokyo, Japan; ³⁸Department of Otorhinolaryngology, Head and Neck Surgery, Hannover Medical School, Hanover, Germany; ³⁹Department of Otorhinolaryngology-Head and Neck Surgery, Medical Center—University of Freiburg, Faculty of Medicine, University of Freiburg, Freiburg im Breisgau, Germany; ⁴⁰Department of Otolaryngology-Head and Neck Surgery, University of Texas Southwestern Medical Center, Dallas, Texas, USA; ⁴¹Clinical Research Department, MED-EL GmbH, Innsbruck, Austria; and ⁴²Isra Aljazeera shared first author.

Copyright © 2024 The Authors. Ear & Hearing is published on behalf of the American Auditory Society, by Wolters Kluwer Health, Inc. This is an open-access article distributed under the terms of the Creative Commons Attribution-Non Commercial-No Derivatives License 4.0 (CCBY-NC-ND), where it is permissible to download and share the work provided it is properly cited. The work cannot be changed in any way or used commercially without permission from the journal.

Supplemental digital content is available for this article. Direct URL citations appear in the printed text and are provided in the HTML and text of this article on the journal's Web site (www.ear-hearing.com).

MATERIALS AND METHODS

This study was conducted abiding by the International Research Code of Ethics (1990).

Panel Members

The core committee consisted of four audiologists (A.L., G.M., J.K., and I.A.), three otologists (P.S., I.Aj., and O.A.), two biomedical engineers (Angel Ramos-de-Miguel, Y.A.), and a professional researcher (P.C.), led by a chair (F.A.) from three continents (America, Asia, and Europe). The core committee was responsible for approving the statements derived from the literature and revising the statements according to the voting committee comments for the next rounds of voting. They were also responsible for choosing a voting committee that represented different clinical practices across the different geographic regions. The members of the core committee gathered via video conference meetings before each voting session to approve the statements for voting.

Thirty-nine practitioners were invited to serve as voting committee members. These invitations were made based on experience and expertise, as well as on geographic and institutional dispersion. Of the 34 who agreed to participate as voting members, the response rate was 94% (32/34). Upon accepting the invitation to participate, all panel members, including the core members and the voting committee members, were given an in-depth briefing on the design and goals of the study, and on their roles.

The four steering members of the core committee (P.C., I.A., I.Aj., and Y.A.) and the chair (F.A.) did not participate in the voting rounds, while the remaining members of the core and voting committees participated in the voting, making a total of 32 voters.

Generation of Consensus Statements

A preliminary literature review and discussions among the core committee members were used to identify intraoperative tests currently in use in the field. The list of tests for which consensus statements were generated consisted of twelve individual tests across three domains (imaging methods, electrophysiology, and implant functionality).

From this, a set of provisional statements was drafted to cover key issues on the purposes and utility of each test. This set of statements was generated through internal discussions among the core and steering committees. After refinement and consolidation of the statement list by the core committee, a final list of 29 statements was produced.

Consensus Voting Procedure

This study used a modified Delphi three-round consensus voting method, in which participants had the opportunity to accept, reject, or suggest revisions for each statement. The Delphi method is a system of repeated rounds of voting, to reach a consensus for a defined clinical problem for which there may be little or no definitive evidence. This procedure has been previously used to generate best-practice consensus statements (Dalkey & Helmer 1963; Dalkey 1969; Murphy et al. 1998; Powell 2003; Meshkat et al. 2014).

In each round, participants were asked to review the statements and vote on whether they agree or disagree with each

statement. They also had the opportunity to provide comments and suggestions for rewording the statement for the following rounds if consensus was not reached. All responses were anonymous at all stages of voting, and participants were not informed of how the other participants had voted during each round. A minimum consensus level of 80% was required for acceptance of each statement (Lynn 1986). Statements that reached this consensus level were accepted and were not included in the next round of voting.

After the first and the second rounds of voting, the core committee evaluated the comments and suggestions by the voters on all the statements that did not reach a consensus. The core committee revised and reworded these statements based on the comments and suggestions. The revised statements were then presented for the next round of voting.

Voting took place between November 2022 and January 2023. The first two rounds were implemented on the online SurveyMonkey platform (www.surveymonkey.com; SurveyMonkey, Palo Alto, CA). The third round of voting took place in person during the International Federation of Otorhinolaryngology Societies ENT World Congress (IFOS) in Dubai, UAE on January 18, 2023. In this round, each participant cast their vote anonymously using a personal mobile device via Mentimeter software (<https://www.mentimeter.com/>; Mintimeter; Stockholm, Sweden).

RESULTS

Statements Regarding Intraoperative Testing

Twenty-nine statements were voted on in the first voting round. Fifteen of these (52%) reached the $\geq 80\%$ consensus threshold (see Table 1 in Supplemental Digital Content, <http://links.lww.com/EANDH/B419>). These statements were accepted without revision and were not voted on in subsequent rounds. Comments and suggestions for revisions were provided for the remaining 14 statements in the first round. On the basis of this feedback, these 14 statements were revised by the core committee. Two statements were eliminated by the core committee because they had not reached a level of consensus and there was no suggested alteration by the voting members to improve them. Therefore, 12 statements remained to be voted on in the second round.

In the second round of voting, 10 of 12 statements reached the consensus threshold (see Table 1 in Supplemental Digital Content, <http://links.lww.com/EANDH/B419>). The remaining two statements, which did not reach consensus, were subject to a further third round of voting. In the third round, both statements again failed to reach the consensus threshold (Fig. 1). No single statement reached a 100% consensus. The highest consensus reached was 96.6% (in three statements) and the lowest agreed-upon statement was 24% (one statement in the third round). Of the total 29 statements, 51.7% (15 statements) reached consensus in the first round and 86.2% (25 statements) reached consensus eventually.

The mean level of agreement was 89.8% ($\pm 5.6\%$) for the statements that reached consensus in the first round, 89% ($\pm 4.7\%$) for the statements that reached consensus in the second round, and 89.4% ($\pm 5.2\%$) overall for accepted statements. There was a significant increase in agreement from a mean of 72.1% ($\pm 5.1\%$) to 89.4% ($\pm 5.2\%$) after the revisions were made before the second round of voting (paired t test mean difference

of 16.8%, $p < 0.001$). While both statements that reached the third round of voting had an average of 7.8% improvement in the agreement after the first revision, they failed to have an improve in the agreement in the third voting after an open in-person discussion.

The revisions after the first voting round resulted in 83.3% (10/12) of the revised statements reaching consensus, while the two revisions after the second round did not result in any improvement in the percentage of agreement during the third round.

After the final round of statement revision and voting, which produced a list of 25 consensus statements, it was found that two statements had very similar wording in their final form. These were *Measuring electrode impedance is an option to verify the functionality of the electrode array* and *Impedance field telemetry is an option to verify the functionality of the implant*. Due to this overlap, it was proposed to remove the latter statement. This proposal was voted on by the participants, and it was agreed by 97% of participants to delete the statement. Henceforth, the final list includes 24 consensus statements (Table 1 in Supplemental Digital Content, <http://links.lww.com/EANDH/B419>).

DISCUSSION

In this study, we aimed to address the lack of consensus regarding intraoperative testing during CI surgery by generating a core set of consensus statements derived from the expertise of an international group of expert practitioners. The resulting framework provides evidence-based guidelines to assist surgeons and clinicians in selecting and conducting the most informative intraoperative tests.

In the following sections, each statement that reached consensus is grouped by the test which was evaluated.

Imaging

- Plain film x-ray can be used to rapidly verify implant and array placement. It can be performed by a radiography technician with portable equipment.
- A combination of imaging and audiological testing should be used for confirmation of electrode placement and function.
- A minimum of one appropriately performed radiological image is recommended after insertion to confirm electrode position and to be used as a base for any future comparisons if electrode migration is suspected.
- CT can verify array placement and can detect misplacements such as tip fold-over and translocations.
- Fluoroscopy is an option in difficult anatomical situations to guide array insertion in real-time to diagnose the misplacement and give an opportunity for placement correction.
- Fluoroscopy should not be used in routine cases due to high radiation exposure.
- It is an option to delay the radiological images to the postoperative period (before discharge from the hospital) in cases with low surgical suspicion of inappropriate insertion and the presence of confirmatory ECAP.
- It is an option to perform the radiological image confirmation in the operating room to reduce the need for unnecessary revision surgery.

Radiological imaging is used to visualize the location and placement of the implant and electrode array because both are

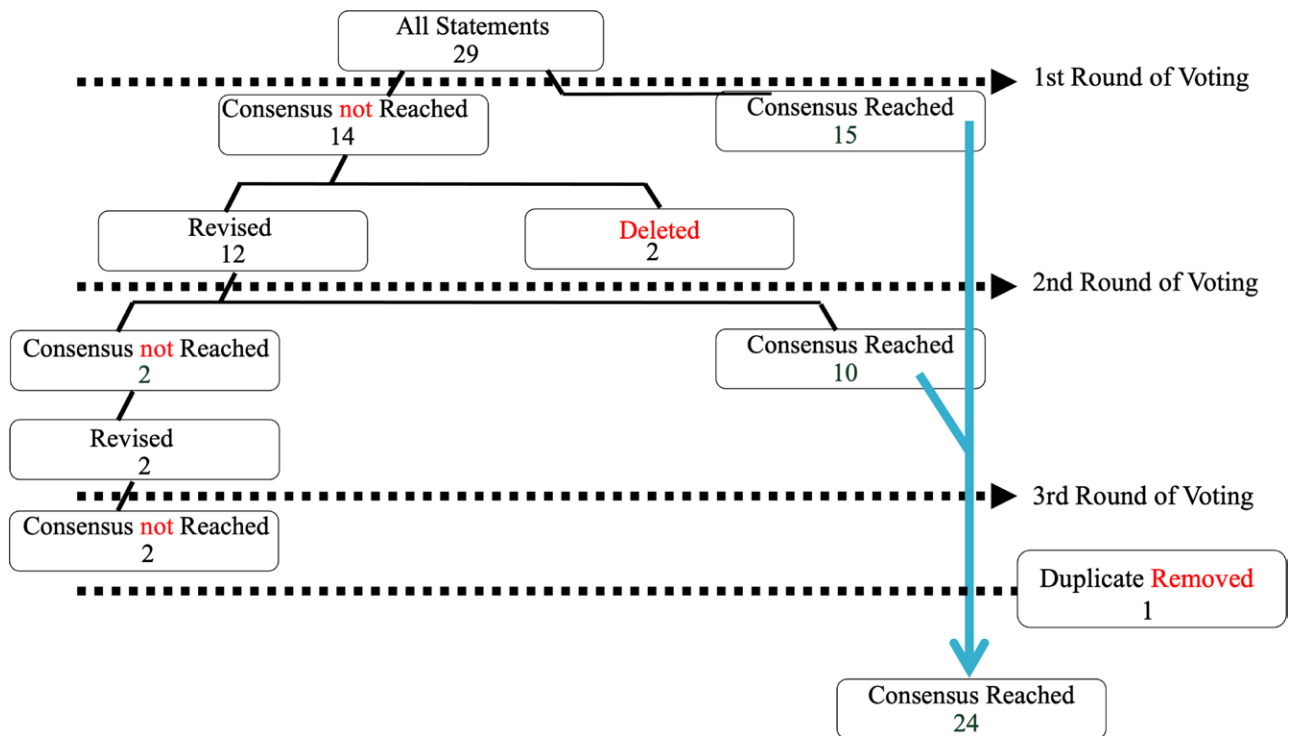


Fig. 1. Summary of the modified Delphi voting procedure and results.

radio opaque. Several imaging modalities can be used for this purpose, including plain x-ray, fluoroscopy, cone beam CT, and high-resolution multidetector CT. When selecting an imaging modality, the surgeon should take into consideration the degree of radiation exposure relative to the gain in the quality of the image that will change decision-making (Razafindranaly et al. 2016; Burck et al. 2021; Helal et al. 2021).

Imaging is commonly performed postoperatively to confirm the location and position of the electrode array. The intraoperative use of imaging has the advantage of allowing for in-site correction of any misplacement of the array. Different practices exist that either advise for a routine intraoperative or postoperative radiological confirmation of the electrode array placement (Vogl et al. 2015). About half of misplaced electrode array cases could be missed if intraoperative imaging is used for suspicious cases only. However, the rate of misplacement in routine cases with normal anatomy is relatively rare (Dirr et al. 2013). Furthermore, the abnormalities in the electrode array placement in the postoperative imaging are usually minor in routine cases therefore not altering management. Thus, the need for intraoperative in comparison to postoperative imaging in routine cases is a matter of debate (Coombs et al. 2014).

X-ray is often referred to as the standard imaging technique by numerous CI centers (Marsh et al. 1993; Czerny et al. 1997, 2000; Lawson et al. 1998; Bettman et al. 2003; Todd & Ball 2004). The routine use of imaging techniques with higher radiation exposure does not appear to be justified, especially in children (Aschendorff 2011). Conventional x-ray, however, lacks the Three Dimensional visualization that high-resolution CT provides that might be needed in special situations. Disadvantages of high-resolution CT include high radiation exposure and some element of image degradation by beam-hardening artifacts that can prohibit the delineation of each electrode contact (Whiting

et al. 2001; Husstedt et al. 2002). The more recent cone beam CT imaging technique imposes a lower radiation dose and induces less artifacts compared with high-resolution CT, making it more suitable for post-CI patients (Ruivo et al. 2009).

Intraoperative fluoroscopy is another imaging technique reported to be useful in difficult cases where the intracochlear placement of the electrode is unforeseeable, such as in cases with severe cochlear anomalies or intracochlear ossification (Fishman et al. 2003; Perez et al. 2014; Perazzini et al. 2020).

Electrode Impedance

- Measuring electrode impedance is an option to verify the functionality of the electrode array.
- Impedance measurements alone cannot be used to confirm intracochlear electrode placement.
- Transimpedance matrix measurements, field telemetry, electric field imaging, and similar tools are useful when suspecting tip fold-over.

Impedance is the opposition to electrical current flow when voltage is applied. In the context of CIs, electrode impedance is produced through a combination of the resistances of the electrode-electrolyte interface and the surrounding tissue (Busby et al. 2002). Impedance telemetry can be used intraoperatively to confirm some aspects of the device functionality and offers some degree of predictive utility for postoperative electrode function (Goehring et al. 2013). However, this technique should be used with caution. Electrode impedance can be measured even if the electrode contact is situated outside of the cochlea. This measurement, therefore, cannot be used alone for confirmation of intracochlear array placement. An abnormally high impedance can be observed during the surgery due to the presence of air bubbles.

Transimpedance is an estimate of the electrical field spread within the cochlea. An impulse is generated at a single stimulating contact, and the voltage distribution is measured from the other array contacts (Wagner et al. 2020). Transimpedance measurements can also be used to confirm some aspects of the device functionality and functionality of the electrodes, and to detect array tip fold-over with a high degree of sensitivity and specificity (De Rijk et al. 2020; Hans et al. 2021; Kay-Rivest et al. 2022).

Facial Nerve Monitoring

- Facial nerve monitoring can alert the surgeon to the proximity of the facial nerve during the operation. Monitoring is carried out via EMG recordings taken from the orbicularis oculi and orbicularis oris muscles. As the monitoring takes place concurrently with the surgical procedure, it does not add a great deal of time to the operation.
- Use of facial nerve monitoring is recommended during all cochlear implantation cases.
- The surgeon should not depend on facial nerve monitoring alone for localization of the facial nerve due to the possibility of device malfunction.

Cochlear implantation is most commonly performed through a facial recess approach, which is a triangular pathway bounded by the facial nerve, the chorda tympani, and the fossa incudis (Thom et al. 2013; Aljazeera et al. 2023). Facial nerve palsy is a rare but devastating complication of cochlear implantation, resulting in substantial social, functional, and financial burdens to the affected patient (Alzhrani et al. 2016). Iatrogenic intraoperative facial nerve palsy is the second most common reason for legal claims in otologic surgeries (Ruhl et al. 2013).

The use of facial nerve monitoring is suggested to decrease the risk of intraoperative facial nerve injury. Although the monitoring does not directly prevent injury to the nerve, the level of stimulation needed to elicit a response correlates with the thickness of the bone protecting the nerve. Therefore, the surgeon can be aware of how much drilling will be needed to reach an appropriate skeletonization to achieve the optimal facial nerve recess opening required for electrode array placement. The monitor can alert the surgeon to inadvertent excessive drilling and thinning of the bone over the facial nerve when the response is elicited by lower levels of stimulation (Noss et al. 2001). However, this benefit cannot be achieved if the surgeon drills a thick bone over the nerve without repeating the stimulation to calibrate the thickness. Furthermore, stimulation needs to be evaluated throughout the intended drilling area, as heterogeneous bone thickness over the facial nerve is not unusual.

Electrically Evoked Compound Action Potentials

- An appropriately performed intraoperative electrically evoked compound action potential (ECAP) is an option to confirm the integrity of the auditory nerve.
- Spread of excitation can be evaluated by measuring ECAPs at each nonstimulating electrode. Spread of excitation is an option to help detect tip fold-overs. An appropriately performed radiological image should be obtained if tip fold-over is suspected.
- ECAP measurements can assess both the integrity of the auditory nerve and the ability of the implant to stimulate it.

ECAP is a direct measurement of the synchronized auditory nerve response initiated by the electrical stimulus presented by the intracochlear electrode. It reflects the functional status of the auditory nerve. This response can be measured passively, irrespective of the patient's arousal status (He et al. 2017). To achieve alignment of CI fitting with auditory perception, the electrode contacts should ideally only stimulate sensory neurons in their immediate proximity. However, this is confounded by the spread of the electrical current field within the cochlea, resulting in the stimulation of adjacent sensory neurons, a phenomenon known as the spread of excitation (Kopsch et al. 2022).

The spread of excitation can be estimated similarly to the spread of stimulation with transimpedance matrix—an impulse is generated at a single stimulating contact, and ECAPs are measured from the other array contacts (Söderqvist et al. 2021). This technique has the additional benefit in that it can be reliably used to detect array tip fold-over with a high degree of sensitivity and specificity (Zuniga et al. 2017; Hans et al. 2021) which manifests as an upward second curve or maximum on the ECAP distribution plot (Grolman et al. 2009).

Electrical Auditory Brainstem Response

- The electrically evoked auditory brainstem response (EABR) can be used to assess both the integrity of the auditory nerve and ascending pathway, and the ability of the implant to stimulate it.
- EABR is recommended as a positive prediction for patients with prolonged hearing loss and cases of cochlear nerve hypoplasia and aplasia. A negative EABR should not be used as a contraindication of CI in these cases.
- When implantation is performed with vestibular schwannoma resection, it is advisable to assess EABR. This can help guide the decision about whether a CI is advisable in this case. Electrically evoked stapedial reflexes (ESRs) can also be assessed to measure functional stimulation of the auditory system.

EABR can be assessed either with the current CI or using a test electrode to decide if cochlear implantation is advisable. This tool is a disposable device that can be very useful in cases in which the status of the cochlear nerve is questionable. EABR is a measure of the electrically evoked response of the sequential firing of auditory brainstem structures downstream of the auditory nerve. It is typically recorded with surface electrodes (Wang et al. 2018). In practice, it is used to assess the functional status of the auditory nerve, and possible cochlear nerve aplasia (Maxwell et al. 1999). This can help determine the correct choice between cochlear implantation versus auditory brainstem implantation to treat profound hearing loss (Cinar et al. 2017). Before cochlear implantation, a test electrode can be used to assess the status of the cochlear nerve (Lassaletta et al. 2017). This method has high sensitivity and specificity for predicting auditory perception with a CI following vestibular schwannoma resection (Medina et al. 2020). The absence of an EABR, however, does not always mean an absence of a functioning cochlear nerve, and therefore should not preclude the option of cochlear implantation.

Adult patients with prolonged hearing loss manifest delayed wave V and longer III to V inter-wave intervals when compared with patients with shorter durations of hearing loss (Lammers

et al. 2015). The increased III to V inter-wave interval is correlated with lower auditory performance (Danieli et al. 2022). EABR thresholds were found to be higher in patients with cochlear nerve hypoplasia (Wang et al. 2018). The combination of preoperative magnetic resonance imaging and EABR is a stronger predictor of CI performance in patients with cochlear nerve aplasia/hypoplasia (Yamazaki et al. 2015). Other studies have found the presence of an EABR to be a good predictor of auditory responses, while the absence of an EABR had a poor ability to predict the absence of auditory responses with a CI after vestibular schwannoma resection and in auditory brainstem implant users (O'Driscoll et al. 2011; Di Pasquale Fiasca & Tealdo 2023). EABR can also be used to guide hearing preservation during tumor removal (Patel et al. 2020; Butler et al. 2021).

Electrically Evoked Stapedial Reflex

- Intraoperative electrically evoked stapedial reflex (ESR) is an option to assess the intracochlear placement of the electrode and the integrity of the auditory nerve and ascending stapedial pathway.
- Intraoperative electrically evoked stapedial reflex threshold (ESRT) is an option to estimate stimulation levels that can guide in programming, especially in young children.

The acoustic stapedial reflex is a spontaneous contraction of the stapedius muscle in response to a vigorous acoustic stimulus. For the stapedial reflex to be present, both the ascending and descending pathways of the reflex need to be functioning (Wiley & Fowler 1997). The stapedial reflex is assumed to be a protective mechanism against loud noises (Counter & Borg 1993). Due to this property, ESRT is commonly used as a proxy to estimate the maximum comfortable level of electrical stimulation in CI users. It may be particularly useful in young children and those who cannot provide subjective sound perception response (Lorens et al. 2004; Walkowiak et al. 2010; Guo et al. 2021; Palani et al. 2022).

Intraoperative ESR is elicited by the electrical stimulus of the electrode array, while the response is observed visually by inspecting the stapedius muscle contraction under the microscope (Stephan & Welzl-Muller 2000; Gordon et al. 2004).

Electrocochleography

- Electrocochleography (ECochG/ECOG) can be used to monitor for cochlear trauma and to predict postoperative hearing outcomes. ECochG recording can be taken via an electrode placed either on the round window or within the scala tympani. It can be assessed at a single frequency or multiple frequencies. Traces can be directly displayed on the surgery microscope.

In ECochG, an intracochlear electrode is used to record electrical responses from the cochlea to sound. Real-time monitoring of intracochlear ECochG during implant surgery can be used to monitor cochlear function. When the cochlear function is degraded, the residual hearing is poorer (O'Leary et al. 2020). As yet, there is no consensus on the response characteristic that best predicts hearing loss. Several approaches have been explored, including the presence or absence of a fluctuation (or a drop) in the amplitude of the ECochG signal (Campbell et al. 2016) or the magnitude of the drop (Weder et al. 2020). ECochG

can provide real-time feedback during CI surgery (Barnes et al. 2020).

Subjective Testing

- Subjective testing should not be used alone and cannot replace objective testing.

Intraoperative subjective sound perception in the form of sound detection can be used in adult patients who undergo CI surgery under local anesthesia. This can be used after the electrode insertion by electrical stimulation of the device to illicit sound perception. It can also be used in patients with residual hearing in which hearing preservation is intended. An attenuation in the subjective sound perception, in the form of loudness, is associated with a reduction in intraoperative real-time ECochG amplitude during electrode insertion (Linder et al. 2022).

Four statements did not reach consensus: two of them were deleted by the core committee and the other two failed to reach consensus even after two rounds of revision and three rounds of voting. The two statements that were deleted by the core committee were statement 26 (*Intraoperative stimulation of the facial nerve can help in identifying the stapedial tendon, and hence the Round Window, by stimulating its contraction in cases with difficult anatomy*) and statement 27 (*ESRTs [electrically evoked stapedial reflex threshold] can be used to measure functional stimulation of the auditory system and guide decision-making in cases of vestibular schwannoma resection*). Statement 26 received 62% agreement, while statement 27 received 50% agreement in the first round. Because voters could not refine these two statements, the core committee agreed to delete them.

The two statements that failed to reach consensus in the first voting round were statement 28 (*If the cochlear implantation is done under local anesthesia, subjective sound perception is an option to assess the function of the implant*), and statement 29 (*Measuring four-point impedance is an option to detect trauma-induced blood infiltration into the cochlea and predict postoperative hearing loss*). In the feedback comments, several respondents remarked that they had no personal experience with the four-point impedance technique. Several also remarked that the technique is quite new and experimental, and therefore it has not yet reached sufficient diffusion into clinical practice. Therefore, it is premature to make judgments on its efficacy or utility. For this reason, it should be emphasized that the lack of arrival at a consensus on this statement should not be construed as an affirmative statement about the efficacy or utility of this technique.

For the statement regarding subjective sound perception, several commenters remarked that this technique can only be performed under local anesthesia, which is both rare and used only by a minority of practitioners. Several respondents emphasized that general anesthesia is the standard practice. Other objections that were raised include: intraoperatively acquired audiograms may not be reliable; residual hearing in the opposite ear may confound the assessment is used to test the functionality of the implant; under local anesthesia, any movement by the patient should be avoided; there is a general lack of data confirming the relationship between intraoperative sound perception and postoperative hearing preservation outcomes. Furthermore, following the final round of revisions, two statements were found to overlap, as they referred to how

helpful the “impedance” and “impedance field telemetry” are in verifying the functionality of the electrode array. So, one statement was proposed for removal, resulting in a final list of 24 consensus statements.

CONCLUSIONS

This set of 24 consensus statements describes the various intraoperative tests that are available during CI surgery and their potential for utility. It was developed by experts of various backgrounds—CI surgeons, audiologists, and biomedical engineers. The expert panel reached a consensus on several practical statements that clarify the diagnosis, management, and decision-making of CI patients. The paper intends to present this consensus to promote appropriate care of CI patients and provide a guide for practitioners.

ACKNOWLEDGMENTS

The authors thank Dovile Jankunaite who participated in data collection.

F.A. had substantial contribution to the concept and design, supervised and led the project, and critically revised the article. P.C. had substantial contribution to the concept, data analysis, and drafting of the article. I.Aj. had substantial contribution to the concept and design, data analysis, and drafting of the article. Y.A. had substantial contribution to the concept, data analysis, and critically revising the article. All authors had substantial contributions to the concept, participated in the scientific content, and participated in voting for the consensus statements. All authors discussed the results and implications and commented on the manuscript at all stages and critically revised the final article.

The data of this article are available upon request from the corresponding author.

The authors have a closely related manuscript titled: “Minimum Intraoperative Testing Battery During Cochlear Implantation: The Current International Practice Trend” that has been submitted to another journal.

The authors have no conflicts of interest to disclose.

Address for correspondence: Farid Alzhrani, King Abdullah Ear Specialist Center, College of Medicine, King Saud University Medical City, King Saud University, PO Box 245, Riyadh 11411, Saudi Arabia. E-mail: faalzhrani@ksu.edu.sa

Received October 05, 2023; accepted April 29, 2024

REFERENCES

- Aljazeera, I., Alturaiki, S., Abdelsamad, Y., Alzhrani, F., Hagr, A. (2023). Various approaches to the round window for cochlear implantation: A systematic review. *J Laryngol Otol*, 137, 1064–1082.
- Alzhrani, F., Lenarz, T., Teschner, M. (2016). Facial palsy following cochlear implantation. *Eur Arch Otorhinolaryngol*, 273, 4199–4207.
- Aschendorff, A. (2011). [Imaging in cochlear implant patients]. *Laryngorhinootologie*, 90, S16–S21.
- Barnes, J. H., Yin, L. X., Saoji, A. A., Carlson, M. L. (2020). Electrocochleography in cochlear implantation: Development, applications, and future directions. *World J Otorhinolaryngol Head Neck Surg*, 7, 94–100.
- Bettman, R. H., van Olphen, A. F., Zonneveld, F. W., Huizing, E. H. (2003). Electrode insertion depth in cochlear implantation: Development, applications, and future directions. *World J Otorhinolaryngol Head Neck Surg*, 7, 94–100.
- Buchman, C. A., Gifford, R. H., Haynes, D. S., et al. (2020). Unilateral cochlear implants for severe, profound, or moderate sloping to profound bilateral sensorineural hearing loss: A systematic review and consensus statements. *JAMA Otolaryngol Head Neck Surg*, 146, 942–953.
- Burck, I., Schneider, S. V., Balster, S., Lehn, A., Yel, I., Albrecht, M. H., Helbig, S., Stöver, T., Kaltenbach, B., Vogl, T. J. (2021). Radiohistologic comparison study of temporal bone specimens after cochlear implant electrode array insertion: Is cone-beam CT superior to MDCT? *AJR Am J Roentgenol*, 216, 752–758.
- Busby, P. A., Plant, K. L., Whitford, L. A. (2002). Electrode impedance in adults and children using the Nucleus 24 cochlear implant system. *Cochlear Implants Int*, 3, 87–103.
- Butler, M. J., Wick, C. C., Shew, M. A., Chicoine, M. R., Ortmann, A. J., Vance, J., Buchman, C. A. (2021). Intraoperative cochlear nerve monitoring for vestibular schwannoma resection and simultaneous cochlear implantation in neurofibromatosis type 2: A case series. *Oper Neurosurg (Hagerstown)*, 21, 324–331.
- Campbell, L., Kaicer, A., Sly, D., Iseli, C., Wei, B., Briggs, R., O’Leary, S. (2016). Intraoperative real-time cochlear response telemetry predicts hearing preservation in cochlear implantation. *Otol Neurotol*, 37, 332–338.
- Cinar, B. C., Yarli, M., Atay, G., Bajin, M. D., Sennaroglu, G., Sennaroglu, L. (2017). The role of eABR with intracochlear test electrode in decision making between cochlear and brainstem implants: Preliminary results. *Eur Arch Otorhinolaryngol*, 274, 3315–3326.
- Coombs, A., Clamp, P. J., Armstrong, S., Robinson, P. J., Hajioff, D. (2014). The role of post-operative imaging in cochlear implant surgery: A review of 220 adult cases. *Cochlear Implants Int*, 15, 264–271.
- Counter, S. A., & Borg, E. (1993). Acoustic middle ear muscle reflex protection against magnetic coil impulse noise. *Acta Otolaryngol*, 113, 483–488.
- Czerny, C., Gstoettner, W., Adunka, O., Hamzavi, J., Baumgartner, W. D. (2000). Postoperative Darstellung und Erfassung der Lage und Insertionstiefe von multikanalikulären Cochlear-Implantaten durch die hochauflösende Computertomographie und durch das Nativröntgen [Postoperative imaging and evaluation of the electrode position and depth of insertion of multichannel cochlear implants by means of high-resolution computed tomography and conventional X-rays]. *Wien Klin Wochenschr*, 112, 509–511.
- Czerny, C., Steiner, E., Gstoettner, W., Baumgartner, W. D., Imhof, H. (1997). Postoperative radiographic assessment of the Combi 40 cochlear implant. *AJR Am J Roentgenol*, 169, 1689–1694.
- Dalkey, N. C. (1969). *The Delphi Method: An Experimental Study of Group Opinion*. RAND Corp.
- Dalkey, N., & Helmer, O. (1963). An experimental application of the Delphi method to the use of experts. *Manage Sci*, 9, 458–467.
- Danieli, F., Reis, A. C. M. B., Massuda, E. T., Amaral, M. S. A. D., Hoen, M., Gnansia, D., Hyppolito, M. N. (2022). Clinical implications of intraoperative eABRs to the Evo®-CI electrode array recipients. *Braz J Otorhinolaryngol*, 88, S108–S117.
- De Rijk, S. R., Tam, Y. C., Carlyon, R. P., Bance, M. L. (2020). Detection of extracochlear electrodes in cochlear implants with electric field imaging/transimpedance measurements. *Ear Hear*, 41, 1196–1207.
- Di Pasquale Fiasca, V. M., & Tealdo, G. (2023). Intraoperative cochlear nerve monitoring in cochlear implantation after vestibular schwannoma resection. *Audiol Res*, 13, 398–407.
- Dirr, F., Hempel, J. M., Krause, E., Müller, J., Berghaus, A., Ertl-Wagner, B., Braun, T. (2013). Value of routine plain X-ray position checks after cochlear implantation. *Otol Neurotol*, 34, 1666–1669.
- Fishman, A. J., Roland, J. T., Alexiades, G., Mierzewski, J., Cohen, N. L. (2003). Fluoroscopically assisted cochlear implantation. *Otol Neurotol*, 24, 882–886.
- Goehring, J. L., Hughes, M. L., Baudhuin, J. L., Lusk, R. P. (2013). How well do cochlear implant intraoperative impedance measures predict postoperative electrode function? *Otol Neurotol*, 34, 239–244.
- Gordon, K. A., Papsin, B. C., Harrison, R. V. (2004). Toward a battery of behavioral and objective measures to achieve optimal cochlear implant stimulation levels in children. *Ear Hear*, 25, 447–463.
- Grolman, W., Maat, A., Verdam, F., Simis, Y., Carelsen, B., Freling, N., Tange, R. A. (2009). Spread of excitation measurements for the detection of electrode array foldovers. *Otol Neurotol*, 30, 27–33.
- Guo, H., Lin, B., Chen, T., Li, Y., Guo, M. (2021). The optimal probe tone frequency for eSRT measurements at individual electrodes in children with cochlear implants. *Acta Otolaryngol*, 141, 1055–1062.
- Hans, S., Arweiler-Harbeck, D., Kaster, F., Ludwig, J., Hagedorn, E., Lang, S., Meyer, M., Holtmann, L. C. (2021). Transimpedance matrix measurements reliably detect electrode tip fold-over in cochlear implantation. *Otol Neurotol*, 42, e1494–e1502.
- He, S., Teagle, H. F. B., Buchman, C. A. (2017). The electrically evoked compound action potential: From laboratory to clinic. *Front Neurosci*, 11, 339.

- Helal, R., Jacob, R., Elshinnawy, M., Othman, A., Al-Dhamari, I., Paulus, D., Abdelaziz, T. (2021). Cone-beam CT versus multidetector CT in postoperative cochlear implant imaging: Evaluation of image quality and radiation dose. *AJNR Am J Neuroradiol*, 42, 362–367.
- Husstedt, H. W., Aschendorff, A., Richter, B., Laszig, R., Schumacher, M. (2002). Nondestructive three-dimensional analysis of electrode to modiolus proximity. *Otol Neurotol*, 23, 49–52.
- International Research Codes of Ethics. The Nuremberg Code,” 1, 1990. <https://iris.paho.org/handle/10665.2/27102>
- Kay-Rivest, E., McMenomey, S. O., Jethanamest, D., Shapiro, W. H., Friedmann, D. R., Waltzman, S. B., Roland, J. T. (2022). Predictive value of transimpedance matrix measurements to detect electrode tip foldover. *Otol Neurotol*, 43, 1027–1032.
- Kopsch, A. C., Rahne, T., Plontke, S. K., Wagner, L. (2022). Influence of the spread of electric field on neural excitation in cochlear implant users: Transimpedance and spread of excitation measurements. *Hear Res*, 424, 108591.
- Lammers, M. J. W., van Eijl, R. H. M., van Zanten, G. A., Versnel, H., Grolman, W. (2015). Delayed auditory brainstem responses in prelingually deaf and late-implanted cochlear implant users. *J Assoc Res Otolaryngol*, 16, 669–678.
- Lassaletta, L., Polak, M., Huesers, J., Díaz-Gómez, M., Calvino, M., Varela-Nieto, I., Gavilán, J. (2017). Usefulness of electrical auditory brainstem responses to assess the functionality of the cochlear nerve using an intracochlear test electrode. *Otol Neurotol*, 38, e413–e420.
- Lawson, J. T., Cranley, K., Toner, J. G. (1998). Digital imaging: A valuable technique for the postoperative assessment of cochlear implantation. *Eur Radiol*, 8, 951–954.
- Linder, P., Iso-Mustajarvi, M., Dietz, A. (2022). A Comparison of ECochG with the subjective sound perception during cochlear implantation under local anesthesia—A case series study. *Otol Neurotol*, 43, e540–e547.
- Lorens, A., Walkowiak, A., Piotrowska, A., Skarzynski, H., Anderson, I. (2004). ESRT and MCL correlations in experienced paediatric cochlear implant users. *Cochlear Implants Int*, 5, 28–37.
- Lynn, M. R. (1986). Determination and quantification of content validity. *Nurs Res*, 35, 382–385.
- Marsh, M. A., Xu, J., Blamey, P. J., Whitford, L. A., Xu, S. A., Silverman, J. M., Clark, G. M. (1993). Radiologic evaluation of multichannel intracochlear implant insertion depth. *Am J Otol*, 14, 386–391.
- Maxwell, A. P., Mason, S. M., O'Donoghue, G. M. (1999). Cochlear nerve aplasia: Its importance in cochlear implantation. *Am J Otol*, 20, 335–337.
- Medina, M. M., Polo, R., Amilibia, E., Roca-Ribas, F., Díaz, M., Pérez, M., Muriel, A., Gavilán, J., Cobeta, I., Lassaletta, L. (2020). Diagnostic accuracy of intracochlear test electrode for acoustic nerve monitoring in vestibular schwannoma surgery. *Ear Hear*, 41, 1648–1659.
- Meshkat, B., Cowman, S., Gethin, G., Ryan, K., Wiley, M., Brick, A., Clarke, E., Mulligan, E. (2014). Using an e-Delphi technique in achieving consensus across disciplines for developing best practice in day surgery in Ireland. *J Hosp Adm*, 3, 1.
- Murphy, M. K., Black, N. A., Lamping, D. L., McKee, C. F., Sanderson, J., Askham, Marteau, T. (1998). Consensus development methods, and their use in clinical guideline development. *Health Technol Assess*, 2, 79–83.
- Nassiri, A. M., Sorkin, D. L., Carlson, M. L. (2022). Current estimates of cochlear implant utilization in the United States. *Otol Neurotol*, 43, e558–e562.
- Noss, R. S., Lalwani, A. K., Yingling, C. D. (2001). Facial nerve monitoring in middle ear and mastoid surgery. *Laryngoscope*, 111, 831–836.
- O'Driscoll, M., El-Deredy, W., Atas, A., Sennaroglu, G., Sennaroglu, L., Ramsden, R. T. (2011). Brain stem responses evoked by stimulation with an auditory brain stem implant in children with cochlear nerve aplasia or hypoplasia. *Ear Hear*, 32, 300–312.
- O'Leary, S., Briggs, R., Gerard, J. M., Iseli, C., Wei, B. P., Tari, S., Rousset, A., Bester, C. (2020). Intraoperative observational real-time electrocochleography as a predictor of hearing loss after cochlear implantation: 3 and 12 month outcomes. *Otol Neurotol*, 41, 1222–1229.
- Palani, S., Alexander, A., Sreenivasan, A. (2022). Evaluation of the electrically-evoked stapedial reflex threshold in pediatric cochlear implant users with high-frequency probe tones. *Int Arch Otorhinolaryngol*, 26, e566–e573.
- Patel, N. S., Saoji, A. A., Olund, A. P., Carlson, M. L. (2020). Monitoring cochlear nerve integrity during vestibular schwannoma microsurgery in real-time using cochlear implant evoked auditory brainstem response and streaming neural response imaging. *Otol Neurotol*, 41, e201–e207.
- Perazzini, C., Puechmaile, M., Saroul, N., Plainfossé, O., Montrieux, L., Bécaud, J., Gilain, L., Chabrot, P., Boyer, L., Mom, T. (2020). Fluoroscopy guided electrode-array insertion for cochlear implantation with straight electrode-arrays: A valuable tool in most cases. *Eur Arch Otorhinolaryngol*, 278, 965–975.
- Perez, R., Salem, R., Roland, J. T., Jr, Sichel, J. Y. (2014). [Fluoroscopic assisted cochlear implantation in children with inner ear malformations]. *Harefuah*, 153, 713–715.
- Powell, C. (2003). The Delphi technique: Myths and realities. *J Adv Nurs*, 41, 376–382.
- Raine, C. (2013). Cochlear implants in the United Kingdom: Awareness and utilization. *Cochlear Implants Int*, 14(Suppl 1), S32–S37.
- Rajan, G., Tavora-Vieira, D., Baumgartner, W. D., Godey, B., Müller, J., O'Driscoll, M., Skarzynski, H., Skarzynski, P., Usami, S. I., Adunka, O., Agrawal, S., Bruce, I., De Bodt, M., Caversaccio, M., Pilsbury, H., Gavilán, J., Hagen, R., Hager, A., Kameswaran, M., Van de Heyning, P. (2017). Hearing preservation cochlear implantation in children: The HEARING Group consensus and practice guide. *Cochlear Implants Int*, 19, 1–13.
- Ramsden, J. D., Gordon, K., Aschendorff, A., Borucki, L., Bunne, M., Burdo, S., Garabedian, N., Grolman, W., Irving, R., Lesinski-Schiedat, A., Loundon, N., Manrique, M., Martin, J., Raine, C., Wouters, J., Papsin, B. C. (2012). European bilateral pediatric cochlear implant forum consensus statement. *Otol Neurotol*, 33, 561–565.
- Razafindranaly, V., Truy, E., Pialat, J. B., Martinon, A., Bourhis, M., Boublay, N., Faure, F., Ltaïef-Boudrigua, A. (2016). Cone beam CT versus multislice CT. *Otol Neurotol*, 37, 1246–1254.
- Ruhl, D. S., Hong, S. S., Littlefield, P. D. (2013). Lessons learned in otologic surgery. *Otol Neurotol*, 34, 1173–1179.
- Ruivo, J., Mermuys, K., Bacher, K., Kuhweide, R., Offeciers, E., Casselman, J. W. (2009). Cone beam computed tomography, a low-dose imaging technique in the postoperative assessment of cochlear implantation. *Otol Neurotol*, 30, 299–303.
- Söderqvist, S., Lamminmäki, S., Aarnisalo, A., Hirvonen, T., Sinkkonen, S. T., Sivonen, V. (2021). Intraoperative transimpedance and spread of excitation profile correlations with a lateral-wall cochlear implant electrode array. *Hear Res*, 405, 108235.
- Stephan, K., & Welzl-Müller, K. (2000). Post-operative stapedius reflex tests with simultaneous loudness scaling in patients supplied with cochlear implants. *Audiology*, 39, 13–18.
- Thom, J. J., Carlson, M. L., Olson, M. D., Neff, B. A., Beatty, C. W., Facer, G. W., Driscoll, C. L. W. (2013). The prevalence and clinical course of facial nerve paresis following cochlear implant surgery. *Laryngoscope*, 123, 1000–1004.
- Todd, N. W., & Ball, T. I. (2004). Interobserver agreement of coiling of MED-EL cochlear implant: Plain X-ray studies. *Otol Neurotol*, 25, 271–274.
- Topsakal, V., Agrawal, S., Atlas, M., Baumgartner, W. D., Brown, K., Bruce, I. A., Dazert, S., Hagen, R., Lassaletta, L., Mlynski, R., Raine, C. H., Rajan, G. P., Schmutzhard, J., Sprinzel, G. M., Staeker, H., Usami, S. I., Van Rompaey, V., Zernotti, M., Heyning, P. V. D. (2022). Minimally traumatic cochlear implant surgery: Expert opinion in 2010 and 2020. *J Pers Med*, 12, 1551.
- Varadarajan, V. V., Sydlowski, S. A., Li, M. M., Anne, S., Adunka, O. F. (2020). Evolving criteria for adult and pediatric cochlear implantation. *Ear Nose Throat J*, 100(1), 31–37.
- Vogl, T., Tawfik, A., Emam, A., Naguib, N., Nour-Eldin, A., Burck, I., Stöver, T. (2015). Pre-, intra- and post-operative imaging of cochlear implants. *Rofo*, 187(11), 980–989.
- Wagner, L., Plontke, S. K., Fröhlich, L., Rahne, T. (2020). Reduced spread of electric field after surgical removal of intracochlear schwannoma and cochlear implantation. *Otol Neurotol*, 41, e1297–e1303.
- Walkowiak, A., Lorens, A., Kostek, B., Skarzynski, H., Polak, M. (2010). ESRT, ART, and MCL correlations in experienced paediatric cochlear implant users. *Cochlear Implants Int*, 11(Suppl 1), 482–484.
- Wang, Z., Liu, Y., Wang, L., Shen, X., Han, S., Wang, W., Gao, F., Liang, W., Peng, K. A. (2018). Characteristics of electrically evoked auditory brainstem responses in patients with cochlear nerve canal stenosis receiving cochlear implants. *Int J Pediatr Otorhinolaryngol*, 104, 98–103.
- Weder, S., Bester, C., Collins, A., Shaul, C., Briggs, R. J., O'Leary, S. (2020). Toward a better understanding of electrocochleography: Analysis of real-time recordings. *Ear Hear*, 41, 1560–1567.

- Wesarg, T., Arndt, S., Aschendorff, A., Laszig, R., Beck, R., Jung, L., Zirn, S. (2016). Intra- und postoperative elektrophysiologische Diagnostik. *HNO*, 65, 308–320.
- Wesarg, T., Arndt, S., Aschendorff, A., Laszig, R., Zirn, S. (2014). Intraoperative audiologisch-technische Diagnostik bei der Cochleaimplantatversorgung. *HNO*, 62, 725–734.
- Whiting, B. R., Bae, K. T., Skinner, M. W. (2001). Cochlear implants: Three-dimensional localization by means of coregistration of CT and conventional radiographs. *Radiology*, 221, 543–549.
- Wiley, T. L., & Fowler, C. G. (1997). *Acoustic Immittance Measures in Clinical Audiology: A Primer*. San Diego: Singular Pub. Group.
- Yamazaki, H., Leigh, J., Briggs, R., Naito, Y. (2015). Usefulness of MRI and EABR testing for predicting CI outcomes immediately after cochlear implantation in cases with cochlear nerve deficiency. *Otol Neurotol*, 36, 977–984.
- Zuniga, M. G., Rivas, A., Hedley-Williams, A., Gifford, R. H., Dwyer, R., Dawant, B. M., Sunderhaus, L. W., Hovis, K. L., Wana, G. B., Noble, J. H., Labadie, R. F. (2017). Tip fold-over in cochlear implantation: Case series. *Otol Neurotol*, 38, 199–206.