

available at www.sciencedirect.com

journal homepage: www.europeanurology.com/eufocus



Guidelines

European Association of Urology Guidelines on Penile Size Abnormalities and Dysmorphophobia: Summary of the 2023 Guidelines

Marco Falcone^{a,*}, Carlo Bettocchi^b, Joana Carvalho^c, Miguel Ricou^d, Luca Boeri^e, Paolo Capogrosso^f, Andrea Cocci^g, Giovanni Corona^h, Murat Gülⁱ, Georgios Hatzichristodoulou^j, T. Hugh Jones^k, Ates Kadioğlu^l, Arif Kalkanli^m, Juan I. Martinez-Salamancaⁿ, Uros Milenkovic^o, L. Afonso Morgado^{p,q}, Giorgio I. Russo^r, Ege Can Serefoglu^s, Tharu Tharakan^t, Paolo Verze^u, Suks Minhas^{t,†}, Andrea Salonia^{v,w,†}

^a Department of Urology, Molinette Hospital, A.O.U. Città della Salute e della Scienza, University of Turin, Turin, Italy; ^b Department of Andrology and Male Genitalia Reconstructive Surgery, University of Foggia, Foggia, Italy; ^c William James Center for Research, Department of Education and Psychology, University of Aveiro, Aveiro, Portugal; ^d Department of Community Medicine, Information and Health Decision Sciences, Faculty of Medicine, University of Porto, Porto, Portugal; ^e Department of Urology, IRCCS Fondazione Ca Granda Ospedale Maggiore Policlinico, Milan, Italy; ^f Department of Urology and Andrology, Ospedale di Circolo and Macchi Foundation, Varese, Italy; ^g Department of Minimally Invasive and Robotic Urologic Surgery and Kidney Transplantation, University of Florence, Florence, Italy; ^h Endocrinology Unit, Medical Department, Maggiore-Bellaria Hospital, Bologna, Italy; ⁱ Department of Urology, School of Medicine, Selcuk University, Konya, Turkey; ^j Department of Urology, Martha-Maria Hospital Nuremberg, Nuremberg, Germany; ^k Centre for Diabetes and Endocrinology, Barnsley Hospital NHS Trust, Barnsley, UK; ^l Department of Urology, Istanbul University School of Medicine, Istanbul, Turkey; ^m Department of Urology, Taksim Education and Research Hospital, Istanbul, Turkey; ⁿ Department of Urology, Hospital Universitario Puerta del Hierro Majadahonda, Madrid, Spain; ^o Department of Urology, University Hospitals Leuven, Leuven, Belgium; ^p Urology Service, Centro Hospitalar Universitário São João, Porto, Portugal; ^q Department of Biomedicine, Faculty of Medicine, Porto University, Porto, Portugal; ^r Urology Section, Department of Surgery, University of Catania, Catania, Italy; ^s Department of Urology, Biruni University School of Medicine, Istanbul, Turkey; ^t Department of Urology, Charing Cross Hospital, Imperial Healthcare NHS Trust, London, UK; ^u Department of Medicine and Surgery, Scuola Medica Salernitana, University of Salerno, Fisciano, Italy; ^v Division of Experimental Oncology/Unit of Urology, Urological Research Institute, IRCCS Ospedale San Raffaele, Milan, Italy; ^w Vita-Salute San Raffaele University, Milan, Italy

Article info

Article history:

Accepted August 31, 2023

Keywords:

Penile size
Abnormalities
Dysmorphophobia
Management strategies
Ethical aspects

Abstract

Context: Recommendations regarding the management of penile size abnormalities and dysmorphophobia are important in guiding evidence-based clinical practice.

Objective: To present a summary of the 2023 European Association of Urology sexual and reproductive health evidence-based recommendations for the management of penile size abnormalities and dysmorphophobia.

Evidence acquisition: A broad and comprehensive scoping exercise covering all areas of the guidelines was performed. Databases searched included Medline, EMBASE, and the Cochrane Libraries. A level of evidence and a strength of recommendation were assigned for each recommendation according to the evidence identified. The evidence cutoff date for the 2023 guidelines is June 1, 2022.

Evidence synthesis: Well-structured studies reporting high level of evidence, with standardized PROMS were deficient on penile size abnormalities and dysmorphophobia. A shared definition for short penis/micropenis was also lacking. Categorisation of penile

[†] Joint senior authors.

* Corresponding author. Department of Urology, Molinette Hospital, A.O.U. Città della Salute e della Scienza, University of Turin, Turin, Italy.

E-mail address: marco.falcone@unito.it (M. Falcone).

<https://doi.org/10.1016/j.euf.2023.08.012>

2405-4569/© 2023 European Association of Urology. Published by Elsevier B.V. All rights reserved.

Please cite this article as: M. Falcone, C. Bettocchi, J. Carvalho et al., European Association of Urology Guidelines on Penile Size Abnormalities and Dysmorphophobia: Summary of the 2023 Guidelines, Eur Urol Focus (2023), <https://doi.org/10.1016/j.euf.2023.08.012>

abnormalities according to congenital, acquired, and dysmorphophobic aetiology is deemed compulsory. A detailed medical and psychosexual history and precise measurements of penile size are essential in the diagnostic pathway. Patients with normal penile size who are seeking penile augmentation should be referred for psychological evaluation for potential dysmorphophobic disorders. Penile length and girth enhancements can be achieved via a multitude of treatments, but a personalised management plan is crucial for satisfactory results. Endocrinological therapies, when indicated, are effective in the prepubertal setting only. Vacuum therapy has a limited evidence base in treatment protocols, although acceptable outcomes have been reported for penile traction therapy. Surgical techniques to enhance penile length and girth have limited evidence and should only be proposed after extensive patient counselling.

Conclusions: Management of penile abnormalities and dysmorphophobia is a complex issue with considerable ethical concerns. The adoption of a structured diagnostic and therapeutic pathway is crucial, as recommended in the guidelines.

Patient summary: Requests for medical/surgical treatments to increase penis size have increased dramatically worldwide. Several conservative and surgical treatments are available. However, few patients receive clear information on the benefits and possible harms of these treatments. These guidelines aim to provide a structured path to guide both physicians and patients in the selection of appropriate treatment(s) to increase penis size.

© 2023 European Association of Urology. Published by Elsevier B.V. All rights reserved.

1. Introduction

Throughout history, the size of the penis has represented a marker of masculinity and has been the focus of intense debate with social, cultural, and ethical implications [1,2]. Cosmetic surgery has the potential to restore self-esteem, reduce anxiety, social phobia, and depressive mood states, and increase an individual's wellbeing and quality of life (QoL) [3,4]. However, some candidates for cosmetic surgery may have psychopathological conditions that might result in negative outcomes [4,5]. In a real-life setting, 84% women reported being satisfied with their male partners' penile size, whereas 55% of the male partners were satisfied with their penile size and 45% reported that they would like to have a larger penis [6]. In addition, a subjective impression of penile size may have a negative effect on sexual function and QoL, impacting sexual life in approximately 10% of men [7]. This prevalence is much higher for patients seeking penile augmentation procedures [8]. With the increasing use of penile augmentation procedures worldwide, it is crucial to provide evidence-based recommendations to guide clinicians in this challenging and controversial area.

2. Definitions and classification

An accurate measurement of the penile shaft is a mandatory step in the assessment of patients complaining of a short penis [9]. A standardised tool to address penile measurements and to guide patients seeking penile augmentation procedures is required. The stretched penile length (SPL), defined as the distance between the pubic symphysis and the apex of the glans, is the commonest metric for penile size. SPL of less than 2.5 standard deviations below the mean for the male's age and race is considered a micropenis [10]. Owing to the heterogeneity of clinical conditions related to short penis, the European Association of Urology

(EAU) Guidelines Panel on Sexual and Reproductive Health defined four consensus-based categories (Table 1).

2.1. Acquired false penile shortness

Acquired adult buried penis (AABP) is widely recognised as the only acquired false penile shortness condition [11,12]. The aetiology underlying the development of AABP is related to chronic inflammation of the penile Dartos fascia, leading to progressive retraction and scarring of the perigenital teguments and resulting in entrapment of the penile shaft in the perigenital tissues [12–14]. Factors contributing to AABP include obesity, aggressive circumcision, penile cancer, and dermatological conditions such as lichen sclerosus [15–17]. AABP is commonly associated with erectile and voiding dysfunction, difficulties in maintaining hygiene, and poor QoL [17–19]. Owing to the heterogeneity of clinical presentation, the different classifications of AABP are based on clinical presentation or the surgical procedure required [11,20,21].

2.2. Congenital intrinsic penile shortness

This category includes the rare clinical presentation of true micropenis, for which the prevalence is 0.9–2.1% [22–25]. Although micropenis may present as a manifestation of an endocrine or genetic disorder [22], it may also exist as an isolated finding without a definitive aetiological cause in 25% of cases [22,26]. Among the pre-existing clinical entities associated with micropenis, bladder exstrophy-epispadias complex (BEEC) is the most studied [17,18].

2.3. Acquired intrinsic penile shortness

This category includes a series of pathological entities that lead to shortening of the corpora cavernosa and may be acute (eg, penile trauma or surgical amputation because of penile cancer) or chronic because of progressive fibrosis

Table 1 – Recommendations for the definition and classification of penile abnormalities and dysmorphophobia

| Recommendation | Strength rating |
|--|-----------------|
| A detailed genital examination should be considered in all men and particularly in men with BMI >30 kg/m ² , a history of lichen sclerosis or penile cancer, or complaints of urinary/sexual difficulties or poor cosmesis to exclude the presence of AABP. | Strong |
| Use classification systems to categorise AABP clinical presentation and surgical management. | Weak |
| Inquire regarding the presence of body dysmorphic disorder/penile dysmorphic disorder in patients with a normal-sized penis complaining of short penile size. | Strong |
| AABP = adult acquired buried penis. | |

involving the corpora cavernosa [27–32]. Among chronic causes of penile shortening, Peyronie's disease (PD), treatment for prostate cancer, particularly radical prostatectomy and radical cystectomy, represent the most common aetiologies [27,33–39].

2.4. Body dysmorphic disorder

Body dysmorphic disorder (BDD) is a clinical diagnosis defined by the American Psychiatric Association (APA) [40] as the strong distress generated by perceived defect (s) or flaw(s) in an individual's physical appearance. This flaw is not observable to others, or, if it exists, it appears only slightly [40]. This condition results in significant impairment in important areas of an individual's social or occupational life. BDD is included among the obsessive compulsive and related disorders [40]. Men with BDD present with an exaggerated focus on the size or shape of their penis. BDD is conceptually different from small penis anxiety (SPA), which refers to excessive anxiety regarding a normal-sized penis. SPA is not included under the APA nomenclature, but men with SPA may be at risk of BDD [41]. All of these definitions exclude men with true micro-penis [40,42].

3. Diagnosis

3.1. Medical and sexual history

The first step in evaluation of short penis is a detailed medical history [43]. Common causes of penile shortness should be evaluated (eg, history of phimosis, priapism, hypospadias/epispadias, penile trauma, penile cancer, prostate cancer, penile pain with or without acquired penile curvature suggestive of PD).

3.2. Physical examination and penile size measurements

A focused physical examination of the genital area is essential. Assessment of penile size and shape is mandatory to plan any subsequent psychological, medical, or surgical treatment. The methods for penile measurement vary among surgeons, but the EAU Guidelines Panel on Sexual and Reproductive Health considers SPL measurement to be the minimum requirement [9,44]. The guideline also recommends additional measurements in both the flaccid

and erect state, if possible. SPL can be measured both dorsally and/or ventrally from the penopubic skin junction to the glans tip, or dorsally from the pubic bone to the glans tip using either a measuring tape or Vernier callipers [45]. For girth, both coronal and mid-shaft measurements should be recorded [46].

3.3. Psychological assessment

A subgroup of men requesting penile augmentation procedures present with psychological vulnerability, including BDD [41]. A set of freely available self-reported tools can be used to screen patients at risk of psychopathology or poorer surgical outcomes, including the Body Dysmorphic Disorder Questionnaire [41]; the Cosmetic Procedure Screening Scale for Penile Dysmorphic Disorder [47]; and the Male Genital Self-Image Scale [48,49]. BDD and other psychopathological comorbidities should be assessed by an accredited mental health specialist.

3.4. Counselling and outcomes assessment

A number of validated questionnaires focusing on sexual and erectile function are available. While not specifically validated for the short penis setting, they may be helpful in assessing baseline sexual function and beliefs about penile size [50–58] (Tables 2 and 3).

3.5. Imaging

There is limited evidence regarding the use of imaging techniques in the assessment of patients complaining of penile size abnormalities. Although penile ultrasound and magnetic resonance imaging may provide additional data regarding penile anatomy, there is no definitive evidence that the additional data obtained via imaging provide extra information above a physical examination to justify routine use in this clinical scenario [9,59,60].

4. Nonsurgical treatment of penile shortness

4.1. Psychotherapy

Psychotherapy is recommended when psychopathological comorbidities are detected or when aversive relationship dynamics may be an underlying factor (Table 4). Addressing patients' and partners' motivations and expectations regarding penile augmentation is a key psychotherapeutic target. Men with BDD express a discrepancy between the perceived and the ideal size of the penis, internalising the belief they should have a larger penis [61]. Psychotherapy should attempt to normalise the concept of variability in genital shape and size [8].

4.2. Penile traction therapy

The evidence for use of penile traction therapy is summarised in Supplementary Table 1 [62–66]. Overall, penile traction therapy seems to be effective in lengthening the penis in both the flaccid (+1.7–2.3 cm) and stretched (+1.3–1.7 cm) state with minimal side effects. It is not effective for penile girth enhancement. The quality of

Table 2 – Questionnaires for the assessment of sexual function and patient beliefs regarding penile size

| |
|--|
| Augmentation Phalloplasty Patient Selection and Satisfaction Inventory |
| Beliefs About Penis Size |
| International Index of Erectile Function |
| Male Sexual Health Questionnaire |
| Erectile Dysfunction Inventory of Treatment Satisfaction |

Table 3 – Recommendations for the diagnosis of penile size abnormalities and dysmorphism

| Recommendation | Strength rating |
|---|-----------------|
| Take a comprehensive medical and sexual history in every patient presenting with a complaint of short penile size. | Strong |
| Use stretched penile measurements (skin junction to the glans tip, or dorsally from the pubic bone to the glans tip) to define penile length. | Strong |
| Consider taking flaccid and erect measurements to assess penile length in detail. | Weak |
| Consider measuring penile girth in every patient presenting with a complaint of short penile size. | Weak |
| Use validated questionnaires to screen for body dysmorphic disorder in cases with a normal-sized penis. | Weak |
| Refer patients with suspected body dysmorphic disorder for mental health counselling. | Strong |
| Use validated questionnaires (eg, IIEF-5, BAPS) to assess baseline sexual function and beliefs concerning penile size. | Weak |
| BAPS = Beliefs About Penis Size; IIEF = International Index of Erectile Function. | |

Table 4 – Recommendations for nonsurgical treatment of short penile size

| Recommendation | Strength rating |
|--|-----------------|
| Consider psychotherapy when psychopathological comorbidities are detected or when aversive relationship dynamics may underlie the request for penile augmentation. | Strong |
| Consider the use of penile traction therapy as a conservative treatment to increase penile length. | Weak |
| Do not use vacuum erection devices to increase penile length. | Weak |
| Use endocrinological therapies to restore penile size in boys with micropenis or disorders of sex development. | Strong |
| Do not use testosterone therapy or other hormonal therapies to increase penile size in men after puberty. | Strong |

evidence is low owing to the lack of randomised controlled trials.

4.3. Vacuum erection devices

Data on the use of vacuum erection devices for penile elongation are scarce. In one study of 27 men whose SPL was <10 cm, use of a vacuum erection device for 6 mo did not result in a significant increase in SPL or flaccid length [67].

4.4. Endocrinological therapies

Hormonal administration (testosterone, human chorionic gonadotropin, follicle-stimulating hormone) has been used

to increase the length of the penis in infant or prepubertal boys with micropenis, with satisfactory effects on penile development [68–70]. No evidence supports the use of hormonal therapies after puberty.

5. Surgical treatment of penile shortness

5.1. Surgical treatment of AABP

The purpose of any surgical approach is to unbury the penile shaft, potentially remove perigenital or excess abdominal tissue, and reconstruct the penis to reduce the risk of recurrence of burying. The goal is to balance an effective surgical procedure aimed at improving patient QoL against minimisation of postoperative complications. Life-style changes and modification of risk factors, particularly weight loss, are widely considered as a proactive approach to minimise AABP surgical complications and should be encouraged before any surgical intervention (Table 5). The outcomes of surgical interventions to manage AABP are summarised in Supplementary Table 2. Variable incidence of recurrence (5.2–75%) and satisfactory functional outcomes have been reported, with significant incidence of postoperative complications (3.5% Clavien-Dindo grade V) [71].

5.2. Surgical treatment of congenital intrinsic penile shortness

5.2.1. Suspensory ligament release

Suspensory ligament release involves an infrapubic surgical incision and release of the ligament which attaches the penis to the pubic bone [72–74]. A combined elongating V-Y skin plasty can also be considered [73]. Outcomes for suspensory ligament release are summarised in Supplementary Table 3. Overall, variable increases in SPL have been reported (1.1–4.3 cm) [56,72–74].

5.2.2. Ventral phalloplasty/scrotoplasty

This intervention is based on a ventral shaft skin plasty to move the penoscrotal angle proximally and increase exposure of the penile shaft [75–77]. The surgical outcomes are summarised in Supplementary Table 3.

5.2.3. Suprapubic lipoplasty/liposuction/lipectomy

This intervention reduced the size of the suprapubic fat pad either via a minimally invasive approach (liposuction) or surgically (lipectomy). The aim of removing the suprapubic fat pad is to increase penile shaft exposure [78,79].

5.2.4. Total phallic reconstruction

Total phallic reconstruction (TPR) is the most complex genital reconstruction. The aim is to create a new phallus with a neourethra, and this technique is reserved for severe penile

Table 5 – Recommendations for surgical treatment of short penile size

| Recommendation | Strength rating |
|---|-----------------|
| Adult acquired buried penis | |
| Extensively counsel patients on the benefits and complications of AABP surgery. | Strong |
| Initiate lifestyle changes and modification of risk factors, particularly weight loss, to minimise AABP surgical complications and to optimise surgical outcomes. | Strong |
| Consider surgical treatment to address AABP. | Strong |
| Congenital intrinsic penile shortness | |
| Perform penile augmentation surgery in high-volume centres. | Strong |
| Use suspensory ligament release, ventral phalloplasty, and suprapubic lipoplasty/liposuction/lipectomy to address penile lengthening. | Weak |
| Extensively discuss possible complications related to suspensory ligament release, ventral phalloplasty, and suprapubic lipoplasty/liposuction/lipectomy. | Strong |
| Use total phallic reconstruction to restore genital anatomy in patients affected by congenital micropenis. | Weak |
| Acquired penile shortness | |
| Do not recommend penile prosthesis implantation, penile disassembly, or sliding techniques to patients seeking penile lengthening options. | Strong |
| Use total phallic reconstruction to restore genital anatomy in genetic males with penile inadequacy due to traumatic loss. | Weak |
| AABP = adult acquired buried penis. | |

insufficiency (eg, congenital micropenis, BEEC). Any perceived benefit should be balanced against possible complications [80]. TPR outcomes are summarised in [Supplementary Table 4](#).

5.3. Surgical treatment of acquired penile shortness

5.3.1. Penile prosthesis implantation

The literature fails to show a direct relationship between penile prosthesis implantation (PPI) and penile length in men with erectile dysfunction and no concomitant PD. Deveci et al. [81] evaluated SPL in men undergoing primary implant surgery for diabetes or radical prostatectomy. Some 72% of the patients reported a subjective decrease in penile length, although there was no statistically significant difference in measured SPL [81]. In another study, 45 patients with PD with no deformity, penile curvature <30°, or severe penile fibrosis/scarring received an AMS 700 LGX implant [82]. The mean SPL improved from 13.1 ± 1.2 cm to 13.7 ± 1.1 cm at 6 mo and 14.2 ± 1.2 cm at 12 mo [82]. In a prospective study in which patients with PD were excluded, erect penile length was compared at baseline (erection achieved via intracavernosal injection) and after PPI inflation. The authors observed a decrease in erect penile length of 0.83 ± 0.25 cm at 6 wk, 0.75 ± 0.20 cm at 6 mo, and 0.74 ± 0.15 cm at 1 yr [83]. A further study in which patients with PD were excluded confirmed these results, as the median preoperative pharmacologically induced length of 14.25 ± 2 cm decreased to a median postprosthesis penile length of 13.5 ± 2.13 cm [84].

5.3.2. Penile disassembly

This technique consists of separation of the penis into its anatomic components and insertion of autologous cartilage into the space created between the glans cap and the tip of corpora cavernosa. Perovic and Djordjevic [85] reported an increase of 3 cm in SPL and 3.1 cm in erect length among 19 patients. Results for this procedure are poorly documented, and significant complications such as glans necrosis have led to controversy regarding its value as a surgical option.

5.3.3. Coropral-lengthening manoeuvres

Penile length restoration via the sliding technique (ST) and concomitant PPI was first described in a small series of three patients with end-stage PD associated with severe shortening, and was further supported by a larger series of 28 patients in a multicentre study [86,87]. Overall, 95% of men were satisfied with their increase in penile length (average 3.2 cm). The modified ST (MoST) and multiple slit technique (MuST) are modifications of the original ST [88,89]. In a series reported by Egydio and Kuehhas [88], 143 patients with penile shortening and narrowing underwent a MoST or MuST procedure. The mean gain in penile length was 3.1 cm. The tunical expansion procedure was performed in 416 patients and yielded an average gain in penile length of 3.3 cm (range 2–6) [89]. Outcomes for these procedures are limited and their utility in clinical practice is questionable owing to severe complications.

5.3.4. Total phallic reconstruction

A radial-artery forearm free flap (RAFFF) is the reconstructive approach most often used for TPR. Falcone et al [29] reported their single-centre experience with ten patients who underwent TPR using RAFFF after traumatic penile loss. The outcomes are summarised in [Supplementary Table 4](#).

6. Penile girth enhancement

In recent years, men have increasingly approached urologists for penile girth enhancement to increase their self-confidence, for cosmesis, or to satisfy their partners [90]. Although request for these surgical techniques have become more frequent, the level of evidence for their use in clinical practice is low, notwithstanding the ethical considerations for surgery in this vulnerable group of patients ([Table 6](#)).

6.1. Injection therapy for penile girth enhancement

6.1.1. Soft tissue fillers

Hyaluronic acid (HA) gel is one of the injectable fillers most commonly used in the field of plastic surgery [43,91]. Application of HA for penile girth enhancement has increased in popularity owing to its biocompatibility and infrequent

Table 6 – Recommendations for management of penile girth enhancement

| Recommendation | Strength rating |
|---|-----------------|
| Counsel patients extensively regarding the risks and benefits of penile girth enhancement techniques. | Strong |
| Do not use silicone, paraffin, or petroleum jelly (Vaseline) to address penile girth enhancement. | Strong |
| Hyaluronic acid, soft tissue fillers, and autologous fat injection can be used to address penile girth enhancement but should not be considered as treatment modalities in men with penile dysmorphic disorder. | Weak |
| Consider the use of penile girth enhancement procedures using grafts as experimental. | Strong |
| Consider the use of biodegradable scaffolds and subcutaneous penile implants (Penuma) to address penile girth enhancement as experimental. | Strong |

mild and temporary side effects. The newly invented cross-linked HA has a more lasting effect over time [92]. Studies on HA injection for penile girth enhancement have reported an increase of 1.4–3.78 cm in penile girth (Supplementary Table 5). Patient satisfaction is high (78–100%) and no severe side effects have been reported [93–97].

Polymethylmethacrylate (PMMA) microspheres have been injected as a wrinkle filler, and an average increase in penile circumference of 3.5 cm was reported in two studies [98,99]. Reported side effects included postoperative swelling and inflammatory reactions, which resolved within a few days. No migration of PMMA microspheres to neighbouring regions was observed.

Poly-L-lactic acid is another widely used soft tissue filler. It exerts enhanced effects by stimulating fibroblast proliferation and increasing collagen deposition in tissues. An average increase of 1.2–2.4 cm in penile girth has been reported. No complications other than temporary local pain and swelling were reported [94,100].

6.1.2. Other fillers

Foreign body injection is still frequently practiced in many countries, either by the patient himself or by health care workers, using various substances such as paraffin, silicone, or petroleum jelly (Vaseline) to increase the circumference of the penis [101]. This induces a chronic granulomatous inflammatory foreign-body reaction [101]. The result of this practice is a pathological condition called sclerosing lipogranuloma of the penis, also referred to as paraffinoma or siliconoma according to the substance used [101]. The resultant inflammatory process ranges from oedema and infection to Fournier's gangrene. Penile reconstructive surgeries may be required to remove lipogranulomas [101–104].

6.2. Surgical treatment for penile girth enhancement

6.2.1. Autologous fat injection

This is a surgical technique based on thinning the lower abdomen with liposuction and injecting the harvested fat tissue into the penile shaft [105–107]. In retrospective studies, an average increase of 2–3.5 cm in penile circumference was reported (Supplementary Table 6). No statistically significant decrease was observed in International Index of

Erectile Function scores and no serious adverse events were reported; a postoperative survey revealed that >75% of patients were satisfied [74,105,108].

6.2.2. Grafting procedures (albuginea and pericavernosal)

Surgical techniques using grafts for penile girth enhancement are controversial. For girth gains of 0–4.9 cm, the incidence of postoperative complications was up to 44.4% (Supplementary Table 7). Until more rigorous multi-institutional studies reporting on complications and validated outcomes are conducted, grafting procedures for penile girth enhancement should be considered experimental.

6.2.3. Biodegradable scaffolds

In this technique, fibroblasts harvested from the patient's own scrotal skin and Dartos tissue are cultured and seeded into microporous biodegradable poly-lactic-co-glycolic acid scaffolds, which are then implanted between the Dartos fascia and Buck's fascia. A limited number of studies have reported a girth gain of up to 4.02 cm [109–111] (Supplementary Table 8).

6.2.4. Subcutaneous penile implants

A silicone penile implant called Penuma (International Medical Devices, Beverly Hills, CA, USA) has recently received US Food and Drug Administration approval and has shown promising results for penile girth enhancement. Penuma is a soft silicone subcutaneous implant that is placed on three-quarters of the penile shaft and fixed to the glans with a polyester mesh [112]. Studies have reported an average increase in penile circumference of 2–5 cm. According to published data, complication rates (usually mild and transient) occur in <5% of cases and the removal rate (1%) for the implant is low [112,113].

7. Ethics

When exploring the ethics of undertaking these procedures, there are a number of medical decision-making principles to consider [114], including personal, clinical, and social factors. In the context of penile augmentation, the personal dimensions are central and complex. On one hand, men with micropenis and functional difficulties should be able to benefit from surgical intervention. On the other hand, men with BDD must be referred for psychological and/or psychiatric interventions, which are the first-line therapies for this disorder. Social issues are complex and multifaceted, but must be considered to prevent unwarranted suffering for patients. However, the central question is whether, in the context of limited health resources and societal pressure, prioritisation of such surgery is deemed appropriate. Finally, the issue of professional responsibility—the responsibility of doctors to reinforce public confidence in the medical profession and to promote the best interests of the patient—must be considered. While interventions may reinforce a patient's trust in the medical profession, we are dealing with a group of highly vulnerable individuals. Therefore, exploration of the various dimensions of a patient's health, particularly the psychological

dimensions, may be much more reinforcing of this trust than simply complying with the patient's requests and providing a surgical intervention with a limited evidence base. Given the current scenario, clinicians should adopt a multi-disciplinary team approach and provide a treatment-based approach that is sensitive to patient needs, while maintaining ethical standards without compromising mental health. Open doctor-patient communication regarding expectations, specific risks, benefits, and alternatives is paramount in facilitating the best possible results in this complicated field.

8. Conclusions

Management of penile abnormalities and dysmorphophobia is a complex issue with numerous ethical implications. The adoption of a structured diagnostic and therapeutic pathway within a multidisciplinary team approach, as recommended by the EAU guidelines, is crucial (Fig. 1). The current EAU guidelines provide the first set of comprehensive

evidence-based recommendations on this topic; however, it should be noted that the majority of recommendations rely on low- to very low-level evidence.

Author contributions: Marco Falcone had full access to all the data in the study and takes responsibility for the integrity of the data and the accuracy of the data analysis.

Study concept and design: Falcone, Bettocchi, Carvalho, Ricou, Minhas, Salonia.

Acquisition of data: Falcone, Bettocchi, Carvalho, Ricou.

Analysis and interpretation of data: Falcone, Bettocchi, Carvalho, Ricou, Minhas, Salonia.

Drafting of the manuscript: Falcone, Minhas, Salonia.

Critical revision of the manuscript for important intellectual content: Boeri, Capogrosso, Cocci, Corona, Gül, Hatzichristodoulou, Jones, Kadioğlu, Kalkanli, Martinez-Salamanca, Milenkovic, Morgado, Russo, Serefoğlu, Tharakan, Verze.

Statistical analysis: None.

Obtaining funding: None.

Administrative, technical, or material support: None.

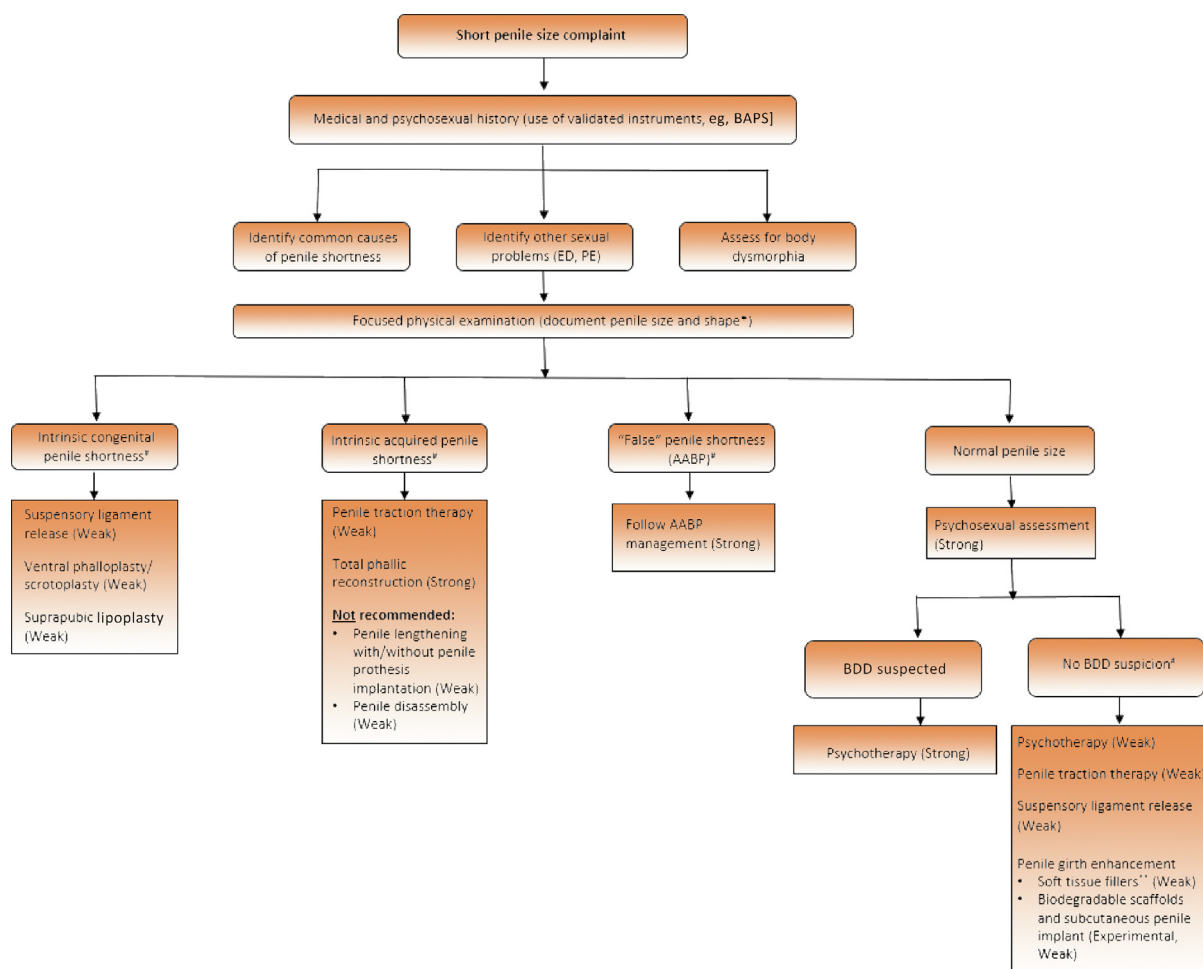


Fig. 1 – Diagnostic and treatment algorithm for the management of short penile size. The strength of recommendation is shown in parentheses where appropriate. AABP = adult acquired buried penis; BAPS = Belief About Penis Size; BDD = body dysmorphic disorder; ED = erectile dysfunction; PE = premature ejaculation. *Penile length should be measured stretched both from the penopubic skin junction to the glans tip, and from the pubic bone to the glans tip. †There is lack of evidence to recommend one treatment over another. **Hyaluronic acid (HA), poly-L-lactic acid (PLA), hydroxyethylmethacrylate, polymethylmethacrylate (PMMA), polyalkylamide hydrogel, and calcium hydroxyapatite are considered as injectable materials for penile girth enhancement. Although the level of evidence is low, there is more evidence for HA, PLA, and PMMA. Do not use silicone, paraffin or Vaseline (strong evidence against).

Supervision: Minhas, Salonia.

Other: None.

Financial disclosures: Marco Falcone certifies that all conflicts of interest, including specific financial interests and relationships and affiliations relevant to the subject matter or materials discussed in the manuscript (eg, employment/affiliation, grants or funding, consultancies, honoraria, stock ownership or options, expert testimony, royalties, or patents filed, received, or pending), are the following: Ege Can Serefoglu is a consultant for and owns stock in Virility Medical, Israel. The remaining authors have nothing to disclose.

Funding/Support and role of the sponsor: This work was supported by the European Association of Urology Guidelines Office. The sponsor played a role in the design and conduct of the study; collection, management, analysis, and interpretation of the data; and preparation, review, and approval of the manuscript.

Appendix A. Supplementary data

Supplementary data to this article can be found online at <https://doi.org/10.1016/j.euf.2023.08.012>.

References

- [1] Gül M, Altintas E, Özkent MS, Fenner A, Serefoglu EC. Depictions of penises in historical paintings reflect changing perceptions of the ideal penis size. *BJU Int* 2023;131:581–7.
- [2] Khan SI, Hudson-Rodd N, Saggers S, et al. Phallus, performance and power: crisis of masculinity. *Sex Relationship Ther* 2008;23:37–49.
- [3] Margraf J, Meyer AH, Lavalley KL. Well-being from the knife? Psychological effects of aesthetic surgery. *Clin Psychol Sci* 2013;1:239–52.
- [4] Ferraro GA, Rossano F, D'Andrea F. Self-perception and self-esteem of patients seeking cosmetic surgery. *Aesthetic Plast Surg* 2005;29:184–9.
- [5] Ghanem H, Glina S, Assalian P, Buvat J. Position paper: management of men complaining of a small penis despite an actually normal size. *J Sex Med* 2013;10:294–303.
- [6] Lever J, Frederick DA, Peplau LA. Does size matter? Men's and women's views on penis size across the lifespan. *Psychol Men Masc* 2006;7:129–43.
- [7] Sanches BC, Laranja WW, Alonso JCC, Rejowski RF, Simões GA, Reis LO. Does underestimated penile size impact erectile function in healthy men? *Int J Impot Res* 2018;30:158–62.
- [8] Smith NK, Butler S, Wagner B, Collazo E, Caltabiano L, Herbenick D. Genital self-image and considerations of elective genital surgery. *J Sex Marital Ther* 2017;43:169–84.
- [9] Greenstein A, Dekalo S, Chen J. Penile size in adult men—recommendations for clinical and research measurements. *Int J Impot Res* 2020;32:153–8.
- [10] Aaronson IA. Micropenis: medical and surgical implications. *J Urol* 1994;152:4–14.
- [11] Tausch TJ, Tachibana I, Siegel JA, Hoxworth R, Scott JM, Morey AF. Classification system for individualized treatment of adult buried penis syndrome. *Plast Reconstr Surg* 2016;138:703–11.
- [12] Keyes EL. *Urology: diseases of the urinary organs, diseases of the male genital organs, the venereal diseases*. New York, NY: Forgotten Books; 1921.
- [13] Falcone M, Sokolakis I, Capogrosso P, et al. What are the benefits and harms of surgical management options for adult-acquired buried penis? A systematic review. *BJU Int* 2023;131:8–19.
- [14] Alter GJ. Pubic contouring after massive weight loss in men and women: correction of hidden penis, mons ptosis, and labia majora enlargement. *Plast Reconstr Surg* 2012;130:936–47.
- [15] Cohen PR. Adult acquired buried penis: a hidden problem in obese men. *Cureus* 2021;13:e13067.
- [16] NCD Risk Factor Collaboration. Trends in adult body-mass index in 200 countries from 1975 to 2014: a pooled analysis of 1698 population-based measurement studies with 19.2 million participants. *Lancet* 2016;387:1377–96.
- [17] Hampson LA, Muncey W, Chung PH, et al. Surgical and functional outcomes following buried penis repair with limited panniculectomy and split-thickness skin graft. *Urology* 2017;110:234–8.
- [18] Hughes DB, Perez E, Garcia RM, Aragón OR, Erdmann D. Sexual and overall quality of life improvements after surgical correction of “buried penis”. *Ann Plast Surg* 2016;76:532–5.
- [19] Knio Z, Kurban M, Abbas O. Lichen sclerosis: clinicopathological study of 60 cases from Lebanon. *Int J Dermatol* 2016;55:1076–81.
- [20] Hesse MA, Israel JS, Shulzhenko NO, et al. The surgical treatment of adult acquired buried penis syndrome: a new classification system. *Aesthet Surg J* 2019;39:979–88.
- [21] Pariser JJ, Soto-Aviles OE, Miller B, Husainat M, Santucci RA. A simplified adult acquired buried penis repair classification system with an analysis of perioperative complications and urethral stricture disease. *Urology* 2018;120:248–52.
- [22] Husmann DA. The androgen insensitive micropenis: long-term follow-up into adulthood. *J Pediatr Endocrinol Metab* 2004;17:1037–41.
- [23] Stuhldreher PP, Inouye B, Gearhart JP. Exstrophy-epispadias complex. *Curr Bladder Dysfunct Rep* 2015;10:227–32.
- [24] Ebert AK, Zwink N, Jenetzky E, et al. Association between exstrophy-epispadias complex and congenital anomalies: a German multicenter study. *Urology* 2019;123:210–20.
- [25] Agopian AJ, Langlois PH, Ramakrishnan A, Canfield MA. Epidemiologic features of male genital malformations and subtypes in Texas. *Am J Med Genet A* 2014;164A:943–9.
- [26] Sasaki G, Ogata T, Ishii T, et al. Micropenis and the 5 α -reductase-2 (SRD5A2) gene: mutation and V89L polymorphism analysis in 81 Japanese patients. *J Clin Endocrinol Metab* 2003;88:3431–6.
- [27] Vasconcelos JS, Figueiredo RT, Nascimento FL, Damião R, da Silva EA. The natural history of penile length after radical prostatectomy: a long-term prospective study. *Urology* 2012;80:1293–6.
- [28] Djordjevic ML, Bizic M, Stojanov B, et al. Outcomes and special techniques for treatment of penile amputation injury. *Injury* 2019;50(Suppl 5):S131–6.
- [29] Falcone M, Garaffa G, Raheem A, Christopher NA, Ralph DJ. Total phallic reconstruction using the radial artery based forearm free flap after traumatic penile amputation. *J Sex Med* 2016;13:1119–24.
- [30] Hoare DT, Bekkema J, Rourke KF. Prospective assessment of patient-perceived short-term changes in penile appearance after urethroplasty. *Urology* 2021;158:222–7.
- [31] Moriya K, Nakamura M, Nishimura Y, et al. Factors affecting post-pubertal penile size in patients with hypospadias. *World J Urol* 2016;34:1317–21.
- [32] Wilson SK, Levine L, Wang R. “Make it as long as you can, Doc”. Concomitant surgical treatments with penile implant to enhance penile size. *Int J Impot Res* 2021;33:587–95.
- [33] Kamel I, Gadalla A, Ghanem H, Oraby M. Comparing penile measurements in normal and erectile dysfunction subjects. *J Sex Med* 2009;6:2305–10.
- [34] Ziegelmann M, Bole R, Avant R, Yang D, Montgomery B, Trost L. Conservatively managed Peyronie's disease—long-term survey results from patients undergoing nonsurgical and noninjection therapies. *Urology* 2018;113:99–104.
- [35] Carlsson S, Nilsson AE, Johansson E, Nyberg T, Akre O, Steineck G. Self-perceived penile shortening after radical prostatectomy. *Int J Impot Res* 2012;24:179–84.
- [36] Haliloglu A, Baltaci S, Yaman O. Penile length changes in men treated with androgen suppression plus radiation therapy for local or locally advanced prostate cancer. *J Urol* 2007;177:128–30.
- [37] Gontero P, Galzerano M, Bartoletti R, et al. New insights into the pathogenesis of penile shortening after radical prostatectomy and the role of postoperative sexual function. *J Urol* 2007;178:602–7.
- [38] Park KK, Lee SH, Chung BH. The effects of long-term androgen deprivation therapy on penile length in patients with prostate cancer: a single-center, prospective, open-label, observational study. *J Sex Med* 2011;8:3214–9.

- [39] Diaz KA, Spiess PE, García-Perdomo HA. Patient-reported outcomes in penile cancer patients: quality of life, sexual and urinary function. What do we know? *Urology* 2022;169:1-5.
- [40] American Psychiatric Association. Diagnostic and statistical manual of mental disorders. ed. 5. Arlington, VA: APA Publishing; 2013.
- [41] Veale D, Miles S, Read J, et al. Penile dysmorphic disorder: development of a screening scale. *Arch Sex Behav* 2015;44:2311-21.
- [42] Wylie KR, Eardley I. Penile size and the 'small penis syndrome'. *BJU Int* 2007;99:1449-55.
- [43] Salonia A, Bettocchi C, Boeri L, et al. European Association of Urology guidelines on sexual and reproductive health—2021 update: male sexual dysfunction. *Eur Urol* 2021;80:333-57.
- [44] Blecher GA, Vukina J, Ralph DJ. Penile dimensions: what are surgeons measuring? *Int J Impot Res* 2019;31:444-50.
- [45] Cakir OO, Pozzi E, Castiglione F, Alnajjar HM, Salonia A, Muneer A. Penile length measurement: methodological challenges and recommendations, a systematic review. *J Sex Med* 2021;18:433-9.
- [46] Joumbat NR, Chim J, Aguirre Sanchez PG, Bedolla E, Salgado CJ. Guidelines for the standardization of genital photography. *Aesthet Surg J* 2018;38:1124-30.
- [47] Phillips KA. The broken mirror: understanding and treating body dysmorphic disorder. New York, NY: Oxford University Press; 2005.
- [48] Herbenick D, Schick V, Reece M, Sanders SA, Fortenberry JD. The development and validation of the Male Genital Self-Image Scale: results from a nationally representative probability sample of men in the United States. *J Sex Med* 2013;10:1516-25.
- [49] Davis SN, Binik YM, Amsel R, Carrier S. The Index of Male Genital Image: a new scale to assess male genital satisfaction. *J Urol* 2013;190:1335-9.
- [50] Rosen RC, Riley A, Wagner G, Osterloh IH, Kirkpatrick J, Mishra A. The International Index of Erectile Function (IIEF): a multidimensional scale for assessment of erectile dysfunction. *Urology* 1997;49:822-30.
- [51] Santos-Iglesias P, Bergeron S, Brotto LA, Rosen NO, Walker LM. Preliminary validation of the Sexual Distress Scale-Short Form: applications to women, men, and prostate cancer survivors. *J Sex Marital Ther* 2020;46:542-63.
- [52] Lawrence KA, Byers ES. Sexual satisfaction in long-term heterosexual relationships: the interpersonal exchange model of sexual satisfaction. *Pers Relationship* 1995;2:267-85.
- [53] Janssen E, Vorst H, Finn P, Bancroft J. The Sexual Inhibition (SIS) and Sexual Excitation (SES) Scales: I. measuring sexual inhibition and excitation proneness in men. *J Sex Res* 2002;39:114-26.
- [54] Nobre P, Gouveia JP, Gomes FA. Sexual Dysfunctional Beliefs Questionnaire: an instrument to assess sexual dysfunctional beliefs as vulnerability factors to sexual problems. *Sex Relationship Ther* 2003;18:171-204.
- [55] Veale D, Eshkevari E, Read J, et al. Beliefs about penis size: validation of a scale for men ashamed about their penis size. *J Sex Med* 2014;11:84-92.
- [56] Spyropoulos E, Galanakis I, Dellis A. Augmentation Phalloplasty Patient Selection and Satisfaction Inventory: a novel questionnaire to evaluate patients considered for augmentation phalloplasty surgery because of penile dysmorphism. *Urology* 2007;70:221-6.
- [57] Rosen RC, Catania J, Pollack L, Althof S, O'Leary M, Seftel AD. Male Sexual Health Questionnaire (MSHQ): scale development and psychometric validation. *Urology* 2004;64:777-82.
- [58] Althof SE, Corty EW, Levine SB, et al. EDITS: development of questionnaires for evaluating satisfaction with treatments for erectile dysfunction. *Urology* 1999;53:793-9.
- [59] Kirkham A. MRI of the penis. *Br J Radiol* 2012;85, Spec No 1: S86.
- [60] Lindquist CM, Nikolaidis P, Mittal PK, Miller FH. MRI of the penis. *Abdom Radiol* 2020;45:2001-17.
- [61] Veale D, Miles S, Read J, et al. Relationship between self-discrepancy and worries about penis size in men with body dysmorphic disorder. *Body Image* 2016;17:48-56.
- [62] García Gómez B, Isa MA, García Rojo E, Fiorillo A, Otero JO. Penile length augmentation surgical and non-surgical approaches for aesthetical purposes. *Int J Impot Res* 2022;34:332-6.
- [63] Colpi GM, Martini P, Scropo F, Mancini M, Castiglioni F. Efficacy of daily penis stretching technique to elongate the 'small penis'. *Int J Impot Res* 2002;14(Suppl 4):S73.
- [64] Gontero P, Di Marco M, Giubilei G, et al. A pilot phase-II prospective study to test the 'efficacy' and tolerability of a penile-extender device in the treatment of 'short penis'. *BJU Int* 2009;103:793-7.
- [65] Nikoobakht M, Shahnazari A, Rezaeianesh M, Mehraei A, Pourmand G. Effect of penile-extender device in increasing penile size in men with shortened penis: preliminary results. *J Sex Med* 2011;8:3188-92.
- [66] Nowroozi MR, Amini E, Ayati M, Jamshidian H, Radkhah K, Amini S. Applying extender devices in patients with penile dysmorphism: assessment of tolerability, efficacy, and impact on erectile function. *J Sex Med* 2015;12:1242-7.
- [67] Aghamir MK, Hosseini R, Alizadeh F. A vacuum device for penile elongation: fact or fiction? *BJU Int* 2006;97:777-8.
- [68] Ben-Galim E, Hillman RE, Weldon VV. Topically applied testosterone and phallic growth. Its effects in male children with hypopituitarism and micropallus. *Am J Dis Child* 1980;134:296-8.
- [69] Main KM, Schmidt IM, Toppari J, Skakkebaek NE. Early postnatal treatment of hypogonadotropic hypogonadism with recombinant human FSH and LH. *Eur J Endocrinol* 2002;146:75-9.
- [70] Bougnères P, François M, Pantalone L, et al. Effects of an early postnatal treatment of hypogonadotropic hypogonadism with a continuous subcutaneous infusion of recombinant follicle-stimulating hormone and luteinizing hormone. *J Clin Endocrinol Metab* 2008;93:2202-5.
- [71] Harris TGW, Manyevitch R, Wu WJ, et al. Pedicled anterolateral thigh and radial forearm free flap phalloplasty for penile reconstruction in patients with bladder exstrophy. *J Urol* 2021;205:880-7.
- [72] Zhang X, Huang Z, Xiao Y, et al. Suspensory ligament release combined with acellular dermal matrix filler in infrapubic space: a new method for penile length augmentation. *Andrologia* 2019;51: e13351.
- [73] Li CY, Kayes O, Kell PD, Christopher N, Minhas S, Ralph DJ. Penile suspensory ligament division for penile augmentation: indications and results. *Eur Urol* 2006;49:729-33.
- [74] Littara A, Melone R, Morales-Medina JC, Iannitti T, Palmieri B. Cosmetic penile enhancement surgery: a 3-year single-centre retrospective clinical evaluation of 355 cases. *Sci Rep* 2019;9:6323.
- [75] Chen YB, Ding XF, Luo C, et al. A new plastic surgical technique for adult congenital webbed penis. *J Zhejiang Univ Sci B* 2012;13:757-60.
- [76] Xu JG, Lv C, Wang YC, Zhu J, Xue CY. Management of concealed penis with modified penoplasty. *Urology* 2015;85:698-702.
- [77] Yu W, Cheng F, Zhang X, Ruan Y, Yang S, Xia Y. Minimally invasive technique for the concealed penis lead to longer penile length. *Pediatr Surg Int* 2010;26:433-7.
- [78] Ghanem H, ElKhayat YI, Motawi AT, AbdelRahman IFS. Infrapubic liposuction for penile length augmentation in patients with infrapubic adiposities. *Aesthetic Plast Surg* 2017;41:441-7.
- [79] Shaeer OK. Shaeer's technique: a minimally invasive procedure for monsoplasty and revealing the concealed penis. *Plast Reconstr Surg Glob Open* 2016;4:e1019.
- [80] Falcone M, Blecher G, Anfoso M, Christopher AN, Ralph DJ. Total phallic reconstruction in the genetic male. *Eur Urol* 2021;79:684-91.
- [81] Deveci S, Martin D, Parker M, Mulhall JP. Penile length alterations following penile prosthesis surgery. *Eur Urol* 2007;51:1128-31.
- [82] Negro CL, Paradiso M, Rocca A, Bardari F. Implantation of AMS 700 LGX penile prosthesis preserves penile length without the need for penile lengthening procedures. *Asian J Androl* 2016;18:114-7.
- [83] Wang R, Howard GE, Hoang A, Yuan JH, Lin HC, Dai YT. Prospective and long-term evaluation of erect penile length obtained with inflatable penile prosthesis to that induced by intracavernosal injection. *Asian J Androl* 2009;11:411-5.
- [84] Osterberg EC, Maganty A, Ramasamy R, Eid JF. Pharmacologically induced erect penile length and stretched penile length are both good predictors of post-inflatable prosthesis penile length. *Int J Impot Res* 2014;26:128-31.
- [85] Perovic SV, Djordjevic ML. Penile lengthening. *BJU Int* 2000;86:1028-33.
- [86] Rolle L, Ceruti C, Timpano M, et al. A new, innovative, lengthening surgical procedure for Peyronie's disease by penile prosthesis

- implantation with double dorsal-ventral patch graft: the "sliding technique". *J Sex Med* 2012;9:2389–95.
- [87] Rolle L, Falcone M, Ceruti C, et al. A prospective multicentric international study on the surgical outcomes and patients' satisfaction rates of the 'sliding' technique for end-stage Peyronie's disease with severe shortening of the penis and erectile dysfunction. *BJU Int* 2016;117:814–20.
- [88] Egydio PH, Kuehhas FE. Penile lengthening and widening without grafting according to a modified 'sliding' technique. *BJU Int* 2015;116:965–72.
- [89] Egydio PH, Kuehhas FE. The multiple-slit technique (MUST) for penile length and girth restoration. *J Sex Med* 2018;15:261–9.
- [90] Zaccaro C, Subirà D, López-Diez I, Manfredi C, Ascencios-Vargas JP, Moncada-Iribarren I. History and future perspectives of male aesthetic genital surgery. *Int J Impot Res* 2022;34:327–31.
- [91] Steenen SA, Bauland CG, van der Lei B, et al. Head-to-head comparison of four hyaluronic acid dermal fillers for lip augmentation: a multi-center randomized, quadruple-blind, controlled clinical trial. *J Am Acad Dermatol* 2023;88:932–95.
- [92] Huang Y, Yang P. Application of cross-linked and non-cross-linked hyaluronic acid nano-needles in cosmetic surgery. *Int J Anal Chem* 2022;2022:.
- [93] Ahn ST, Shim JS, Bae WJ, Kim SW, Kim JJ, Moon DG. Efficacy and safety of penile girth enhancement using hyaluronic acid filler and the clinical impact on ejaculation: a multi-center, patient/evaluator-blinded, randomized active-controlled trial. *World J Mens Health* 2022;40:299–307.
- [94] Yang DY, Ko K, Lee SH, Lee WK. A comparison of the efficacy and safety between hyaluronic acid and polylactic acid filler injection in penile augmentation: a multicenter, patient/evaluator-blinded, randomized trial. *J Sex Med* 2019;16:577–85.
- [95] Kwak TI, Oh MM, Kim JJ, Moon DG. The effects of penile girth enhancement using injectable hyaluronic acid gel, a filler. *J Sex Med* 2011;8:3407–13.
- [96] Yang DY, Jeong HC, Ahn ST, et al. A comparison between hyaluronic acid and polylactic acid filler injections for temporary penile augmentation in patients with small penis syndrome: a multicenter, patient/evaluator-blind, comparative, randomized trial. *J Sex Med* 2020;17:133–41.
- [97] Yang DY, Jeong HC, Ko K, Lee SH, Lee YG, Lee WK. Comparison of clinical outcomes between hyaluronic and polylactic acid filler injections for penile augmentation in men reporting a small penis: a multicenter, patient-blinded/evaluator-blinded, non-inferiority, randomized comparative trial with 18 months of follow-up. *J Clin Med* 2020;9:1024.
- [98] Casavantes L, Lemperle G, Morales P. Penile girth enhancement with polymethylmethacrylate-based soft tissue fillers. *J Sex Med* 2016;13:1414–22.
- [99] Kim MT, Ko K, Lee WK, Kim SC, Yang DY. Long-term safety and longevity of a mixture of polymethyl methacrylate and cross-linked dextran (Lipen-10[®]) after penile augmentation: extension study from six to 18 months of follow-up. *World J Mens Health* 2015;33:202–8.
- [100] Yang DY, Ko K, Lee SH, Moon DG, Kim JW, Lee WK. Efficacy and safety of a newly developed polylactic acid microsphere as an injectable bulking agent for penile augmentation: 18-months follow-up. *Int J Impot Res* 2017;29:136–41.
- [101] Dellis AE, Arkoumanis T, Kyprianou C, Papatsoris AG. Paraffinoma, siliconoma and Co: disastrous consequences of failed penile augmentation—a single-centre successful surgical management of a challenging entity. *Andrologia* 2018;50:e13109.
- [102] Dellis AE, Nastos K, Mastorakos D, Dellaportas D, Papatsoris A, Arkoumanis PT. Minimal surgical management of penile paraffinoma after subcutaneous penile paraffin injection. *Arab J Urol* 2017;15:387–90.
- [103] Eandi JA, Yao AP, Javidan J. Penile paraffinoma: the delayed presentation. *Int Urol Nephrol* 2007;39:553–5.
- [104] Fakin R, Zimmermann S, Jindarak S, Lindenblatt N, Giovanoli P, Suwajo P. Reconstruction of penile shaft defects following silicone injection by bipedicle anterior scrotal flap. *J Urol* 2017;197:1166–70.
- [105] Kang DH, Chung JH, Kim YJ, et al. Efficacy and safety of penile girth enhancement by autologous fat injection for patients with thin penises. *Aesthetic Plast Surg* 2012;36:813–8.
- [106] Mutluoglu M, Marrannes J, Boel K, De Smet K. Penile girth enlargement: do not try it at home. *Int J Impot Res* 2022;34:108–10.
- [107] Parodi PC, Dominici M, Moro U. Penis invalidating cicatricial outcomes in an enlargement phalloplasty case with polyacrylamide gel (Formacryl). *Int J Impot Res* 2006;18:318–21.
- [108] Salem AM, Osman IAL, Zaghloul AS, Mohamed MS, Sadek MN, Gamalel Din SF. Effect of girth supersizing on patient satisfaction after semi-rigid penile implant insertion: a prospective case-control study. *Aesthet Surg J* 2019;39:NP259–265.
- [109] Djordjevic ML, Bumbasirevic U, Stojanovic B, et al. Repeated penile girth enhancement with biodegradable scaffolds: microscopic ultrastructural analysis and surgical benefits. *Asian J Androl* 2018;20:488–92.
- [110] Jin Z, Wu YG, Yuan YM, et al. Tissue engineering penoplasty with biodegradable scaffold Maxpol-T cogenerated autologous fibroblasts for small penis syndrome. *J Androl* 2011;32:491–5.
- [111] Perovic SV, Byun JS, Scheplev P, Djordjevic ML, Kim JH, Bubanj T. New perspectives of penile enhancement surgery: tissue engineering with biodegradable scaffolds. *Eur Urol* 2006;49:139–47.
- [112] Elist JJ, Valenzuela R, Hillelsohn J, Feng T, Hosseini A. A single-surgeon retrospective and preliminary evaluation of the safety and effectiveness of the Penuma silicone sleeve implant for elective cosmetic correction of the flaccid penis. *J Sex Med* 2018;15:1216–23.
- [113] Siegal AR, Zisman A, Sljivich M, Razdan S, Valenzuela RJ. Outcomes of a single center's initial experience with the Penuma[®] penile implant. *Urology* 2023;171:236–43.
- [114] Childress JF, Beauchamp TL. Common morality principles in biomedical ethics: responses to critics. *Camb Q Healthc Ethics* 2022;31:164–76.